



University of Southern Denmark

**Spontaneous dissolution of a cyst located within the septum pellucidum in a patient with sarcoidosis
a case report**

Kastrup Loft, Martina; Rafaelsen, Søren Rafael; Roland Vils Pedersen, Malene

Published in:
Acta Radiologica Open

DOI:
10.1177/2058460120985519

Publication date:
2021

Document version:
Final published version

Document license:
CC BY-NC

Citation for pulished version (APA):

Kastrup Loft, M., Rafaelsen, S. R., & Roland Vils Pedersen, M. (2021). Spontaneous dissolution of a cyst located within the septum pellucidum in a patient with sarcoidosis: a case report. *Acta Radiologica Open*, 10(1), 1-5. <https://doi.org/10.1177/2058460120985519>

Go to publication entry in University of Southern Denmark's Research Portal

Terms of use

This work is brought to you by the University of Southern Denmark.
Unless otherwise specified it has been shared according to the terms for self-archiving.
If no other license is stated, these terms apply:

- You may download this work for personal use only.
- You may not further distribute the material or use it for any profit-making activity or commercial gain
- You may freely distribute the URL identifying this open access version

If you believe that this document breaches copyright please contact us providing details and we will investigate your claim.
Please direct all enquiries to puresupport@bib.sdu.dk

Spontaneous dissolution of a cyst located within the septum pellucidum in a patient with sarcoidosis: a case report

Acta Radiologica Open
10(1) 1–5
© The Foundation Acta
Radiologica 2021
Article reuse guidelines:
sagepub.com/journals-permissions
DOI: 10.1177/205846012098519
journals.sagepub.com/home/arr



Martina Kastrup Loft^{1,2} , Søren Rafael Rafaelsen^{1,2} and Malene Roland V Pedersen^{1,2} 

Abstract

Sarcoidosis is a granulomatous multisystem disease of unknown etiology. Typically, the disease affects the lungs, causing enlargement of the mediastinal lymph nodes, but other organs can be affected. Neurosarcoidosis is reported in 5–10% of the patients. This case represents a 39-year-old male patient diagnosed with lung sarcoidosis. Due to neurological symptoms, a contrast-enhanced cerebral magnetic resonance imaging was performed. Neurosarcoidosis was presented with meningeal enhancement adjacent to a cyst located within the cavum septum pellucidum. The cyst dissolved spontaneously within six months. The finding of a cyst located within the septum pellucidum is rare.

Keywords

septum pellucidum, cyst, spontaneous dissolution, MRI

Received 15 July 2020; accepted 9 December 2020

Introduction

Sarcoidosis is a granulomatous multi system disease of unknown etiology. Typically, the disease affects the lungs, causing enlargement of the mediastinal lymph nodes, but other organs can be affected. Neurosarcoidosis is reported in 5–10% of the patients.^{1–3} Sarcoidosis is diagnosed based on imaging and examination of cerebrospinal fluid (CSF) and verified by histopathology.⁴ The image modalities typically include chest x-ray, computed tomography (CT) and magnetic resonance imaging (MRI). Neurosarcoidosis occurs in the cerebral meninges, leptomeninges, base of the brain, white matter, chorioidea and vessel walls.⁵ MRI findings of neurosarcoidosis vary and include white matter lesions, meningeal enhancement and parenchymal manifestation, if any.⁶

Cavum septum pellucidum is a thin vertical midline brain structure separating the right and left ventricles. Its function is not yet fully understood. Cysts located within the septum pellucidum are exceptional findings and may cause obstruction leading to hydrocephalus. A commonly accepted definition of this type of cyst is a fluid-containing structure of 10 mm or greater.⁷ Septum pellucidum cysts are often found incidentally during MRI or CT. To the best of our knowledge, a

limited number of cysts within the septum pellucidum dissolves spontaneously without surgery. The dissolution of septum pellucidum cysts in adults has been reported between 15 months and 4 years of follow-up.^{8–10}

We present a case of a 39-year-old man diagnosed with a septum pellucidum cyst during examination of neurosarcoidosis. No previous history of brain tumor, hydrocephalus or head trauma was reported. After six months of MRI follow-up, the cyst had spontaneously dissolved. This case differs from the above cases, as the cyst appeared without communication to the ventricular system.

¹Department of Radiology, Lillebaelt Hospital, Vejle Hospital, Vejle, Denmark

²Institute of Regional Health, University of Southern Denmark, Odense, Denmark

Corresponding author:

Malene Roland V Pedersen, Radiology Department, University Hospital of Southern Denmark, Vejle Beriderbakken 4, DK:7100 Vejle, Denmark.
Email: Malene.Roland.Vils.Pedersen@rsyd.dk



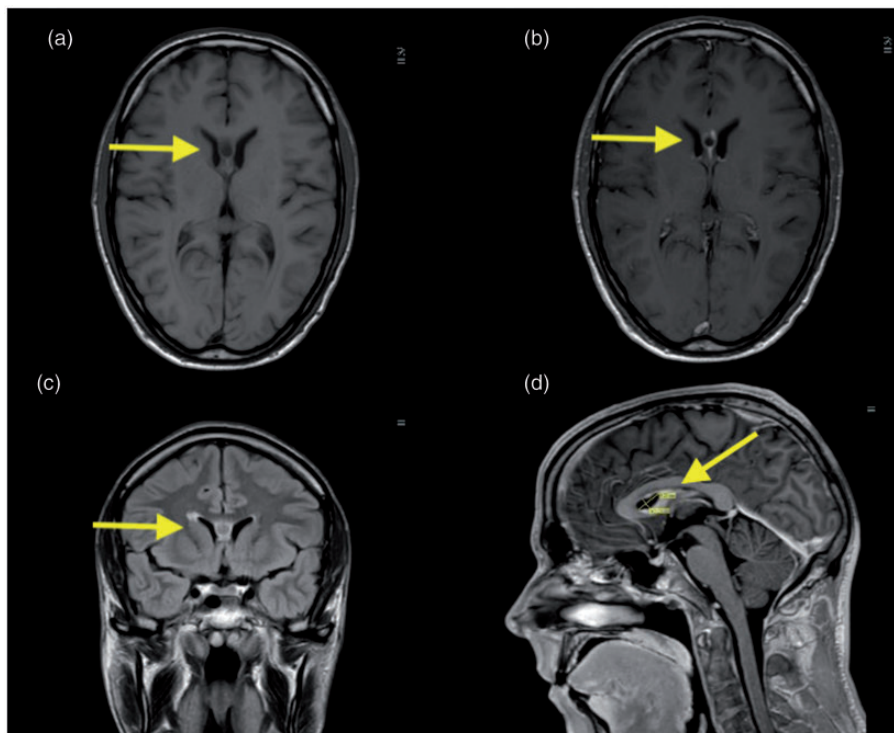


Figure 1. MRI images from the first scan performed. Arrows shows the location of the cyst. (a) T1 (axial plane). The cyst contains fluid. (b) T1 including gadolinium (axial plane). Meningeal enhancement adjacent to the cyst. (c) FLAIR sequence (coronal plane). Fluid inside the cyst differs from the CSF. (d) T1 including gadolinium (sagittal plane). Meningeal enhancement adjacent to the cyst.

Case

A 39-year-old Caucasian male was referred from his general practitioner to a chest CT due to dry cough, including dryness of the throat and mouth. An initial treatment with penicillin had not provided any effect. During the past 12 months, the patient had also experienced soreness in fingers, hand, knees and ankle joints, and sensory disorders in the right arm. A weight loss on 3 kg occurred over two months. No additional central or peripheral symptoms from the nervous system were present. A contrast-enhanced chest CT revealed bilaterally enlarged mediastinal lymph nodes (7×7 cm). The biopsy showed lung sarcoidosis. The patient was treated conservatively without corticoid steroids or immune suppressive therapy.

A contrast-enhanced MRI of the cerebrum was performed to elucidate neurosarcoidosis. The MRI showed a well-defined cyst in the septum pellucidum with perifocal edema in the surrounding tissue. Length, height and width of the cyst was $7 \times 17 \times 9$ mm, respectively (Figure 1). The cyst contained fluid with a slightly increased viscosity compared to the CSF on the T1-fluid attenuated inversion recovery (FLAIR) sequence, suggesting no communication with the ventricular system. Contrast-enhanced T1-weighted imaging revealed no enhancement of the fluid inside the cyst,

but the adjacent meninges showed intense homogeneous enhancement. There was no diffusion restriction. In addition, a couple of discrete white matter lesions was detected. The MRI conclusion was a pathologic cyst in the septum pellucidum and meningeal enhancement, which may be associated with neurosarcoidosis. However, the possibility of a glioma could not be excluded.

The patient underwent extensive neurological examinations without any findings. Due to its location, the cyst was not eligible for a cerebral biopsy. Consequently, a lumbar puncture was performed, the result was inconclusive.

At two months of follow-up, there was regression of the cyst, which measured $5 \times 14 \times 4$ mm in length, height and width, respectively. Furthermore, the MRI showed regression of the meningeal enhancement area adjacent to the septum pellucidum cyst. The patient's symptoms continued to decrease without any treatment. The lung sarcoidosis was followed with pulmonary function test.

During MRI follow-up, the cyst dissolved spontaneously within six months as did the meningeal enhancement. At the final MRI follow-up 17 months after primary diagnosis, the cyst was still dissolved (Figure 2 and 3). The patient recovered well from the

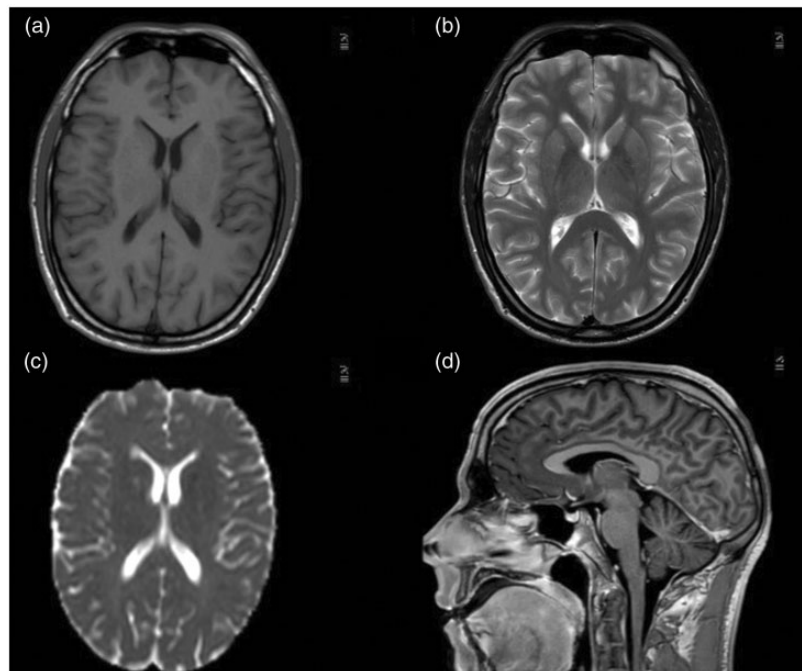


Figure 2. MRI images from the last MRI scan performed. (a) T1 (axial plane). No persisting cyst. (b) T2 (axial plane). No meningeal enhancement. Normal appearance of cerebrum. (c) MRI apparent diffusion coefficient map image (axial plane). Normal appearance of cerebrum. (d) T1 including gadolinium (sagittal plane). No persistent meningeal enhancement.

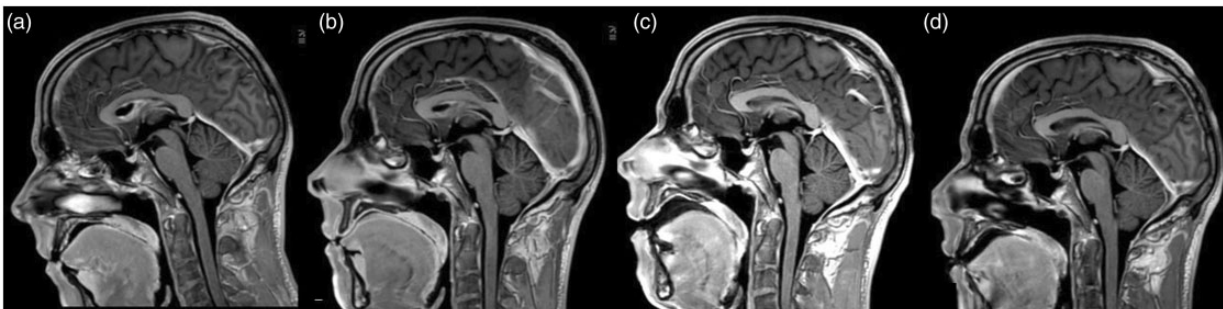


Figure 3. Sagittal cerebrum MRI (T1 including gadolinium) image. (a) Baseline scan. The cyst is present. (b) Two-month of follow-up. The cyst is present. (c) Five-month of follow-up. No visible cyst. (d) 17-month of follow-up. No visible cyst.

sarcoidosis, completed follow-up with the pulmonologist one year after the sarcoidosis diagnosis and is still living well without any symptoms at four years.

Discussion

Neurosarcoidosis is a challenging diagnosis typically based on clinical history, CSF examination, image findings, and histopathologic verification. The clinical neurological manifestation includes cranial nerve affection, headache, seizure, unilateral weakness, cognitive or behavioral dysfunction, and increased intracranial pressure.¹¹ The presentation of the disease on MRI varies and may include meningeal and parenchymal

enhancement, white matter lesions, cranial nerve abnormalities, intramedullary lesions, and degenerative disc disease.¹¹ In the present case, the first MRI revealed meningeal enhancement and few white matter lesions. This indicated neurosarcoidosis to be a likely diagnosis, but the location of the cyst did not allow for histopathological verification. Although the meningeal enhancement was adjacent to the cyst, their relation remains unclear. Thus, it is plausible that the cyst is related to the MRI presentation of neurosarcoidosis. To the best of our knowledge, a case like this has not been reported.

Treatment, depending on the severity of the condition, mainly consists of anti-inflammatory medicaments.¹ In

the present case, the patient received no treatment, and the inflammatory reaction gradually decreased.

The septum pellucidum is the vertical membrane between the corpus callosum and the fornix. The normal thickness is between 1 and 3 mm.⁷ The dissolution of a septum pellucidum cyst has been reported in three studies involving adults^{8–10} and two studies involving children.^{12,13} The prevalence is unknown but appears to be low. A Taiwanese CT study including 19,031 patients reported an intracranial cyst prevalence of 0.93%.¹⁴ Another study investigated 54,000 patients with CT or MRI and found 0.04% with septum pellucidum cysts.¹⁵

This type of cyst may remain asymptomatic throughout a patient's life. Depending on its location the treatment is surgical or conservative. Since image findings may be misinterpreted as oligodendroglioma, giant cell astrocytoma or choroid plexus papilloma, MRI on a regular basis is recommended to follow progression. The present case is unique and represents a cyst spontaneously dissolved within six months. After 17 months of follow-up, it remained dissolved. Other studies have reported cyst dissolution between 15 months and 4 years.^{8–10} Our case differs from others in the literature in that the cyst appeared well-defined and without communication to the ventricular system.

In conclusion, the patient experienced total remission from the neurosarcoidosis, and the cyst dissolved spontaneously. This case suggests that a conservative approach, with a close MRI follow-up, is a feasible option.

Acknowledgement

The authors wish to thank Karin Larsen for English language editing.

Author contribution

ML participated in the study design and wrote the draft. SR was involved in study design, analysis and review of the paper. MP was responsible for the overall scientific management of the study and preparation of the final paper. All authors have read and approved the final manuscript.

Availability of data and materials

All data analyzed or generated during this study are included.

Consent for publication

Written and orally informed consent was provided by the patient. The hospital Review Board approved this study. The study was approved by the local Danish data authorities.

Declaration of Conflicting Interests

The author(s) declared no potential conflicts of interest with respect to the research, authorship, and/or publication of this article.

Funding

The author(s) received no financial support for the research, authorship, and/or publication of this article.

ORCID iDs

Martina Kastrup Loft  <https://orcid.org/0000-0003-3463-8574>

Malene Roland V Pedersen  <https://orcid.org/0000-0001-5167-7968>

References

- Voortman M, Drent M, Baughman R. Management of neurosarcoidosis: a clinical challenge. *Curr Opin Neurol* 2019;32:475–483.
- Fritz D, van de Beek D, Brouwer MC. Clinical features, treatment and outcome in neurosarcoidosis: systematic review and metaanalysis. *BMC Neurol* 2016;16:220.
- Oteruelo FT. On the cavum septi pellucidi and the cavum vergae. *Anat Anz* 1986;162:271–278.
- Hebel R, Dubaniewicz-Wybieralska M, Dubaniewicz A. Overview of neurosarcoidosis: recent advances. *J Neurol* 2015;262:258–267.
- Joseph FG, Scolding NJ. Neurosarcoidosis: a study of 30 new cases. *J Neurol Neurosurg Psychiatry* 2008;80:297–304.
- Tana C, Wegener S, Borys E, et al. challenges in the diagnosis and treatment of neurosarcoidosis. *Ann Med* 2015;47:576–591.
- Sarwar M. The septum pellucidum: normal and abnormal. *AJNR* 1989;10:989–1005.
- Kocer N, Kantarci F, Mihmalli I, et al. Spontaneous regression of a cyst of the cavum septi pellucidi. *Neuroradiology* 2000;42:360–362.
- Sayama CM, Harnsberger HR, Couldwell WT. Spontaneous regression of a cystic cavum septum pellucidum. *Acta Neurochir* 2006;148:1209–1211.
- Hong Y, Chen S, Guo S-X, et al. Spontaneous resolution of a cyst of the septum pellucidum. *Am J Med Sci* 2011;342:333–335.
- Affan M, Mahajan A, Rehman T, et al. The effect of race on clinical presentation and outcomes in neurosarcoidosis. *J Neurol Sci* 2020;417:117073.
- Bot GM, Constantini S, Roth J. Conservative treatment of cysts of the cavum septum pellucidum presenting in childhood: report of 3 cases. *J Neurosurg Pediatr* 2015;16:283–286.
- Sencer A, Sencer S, Turantan Í, et al. Cerebrospinal fluid dynamics of the cava septi pellucidi and vergae. *J Neurosurg* 2001;94:127–129.
- Chen J-J, Chen C-J, Chang H-F, et al. Prevalence of cavum septum pellucidum and/or cavum vergae in brain computed tomographies of Taiwanese. *Acta Neurol Taiwan* 2014;23:49–54.
- Wang KC, Fuh JL, Lirng JF, et al. Headache profile in patients with a dilated cyst of the septum pellucidi. *Cephalgia* 2004;24:867–874.
- Akansel G, Dalbayrak S, Yilmaz M, et al. Abscess of the cavum septum pellucidum. *Pediatr Radiol* 2003;33:503–505.

17. Kihara T, Miyata M. Brain abscess formed in the cavum septi pellucidi. *J Neurol Neurosurg Psychiatry* 2002; 72:411.
18. Vasudev MK, Chavan RG, Nagarajan K, et al. Multi-slice computed tomography appearance of abscess of cavum septum pellucidum: a case report and review of the literature. *Acta Radiol* 2006;47:301–302.
19. Bikmaz K, Dinc C, Cakabay M, et al. Epidermoid cyst of the cavum septum pellucidum. *Acta Neurochir* 2007;149: 1271–1272.
20. Hamlat A, Casallo-Quiliano C, Saikali S, et al. Huge colloid cyst: case report and review of unusual forms. *Acta Neurochir* 2004;146:397–401.
21. Westwick HJ, Obaid S, Morin-Roy F, et al. Imaging of spontaneous intraventricular rupture of a septum pellucidum colloid cyst: case report. *J Neurosurg* 2017;126:1779–1782.
22. Mishra GP, Sharma RR, Musa MM, et al. Endodermal cyst of septum pellucidum and pregnancy: A case report. *Surg Neurol* 2000;53:583–585.
23. Tuchman A, Kalhorn SP, Mikolaenko I, et al. Cystic choroid plexus papilloma in the cavum septum pellucidum. *J Neurosurg Pediatr* 2009;4:580–583.
24. Chen CJ. Expanding septum pellucidum cyst due to a traumatic ventriculoperitoneal shunt. *Neuroradiology* 1999;41:567–569.
25. Scoffings DJ, Kurian KM. Congenital and acquired lesions of the septum pellucidum. *Clin Radiol* 2008;63:210–219.