

A case of preventable pulmonary tuberculosis in a Greenlandic, heavily immune suppressed patient

Christensen, Anne-Sophie H; Johansen, Isik S

Published in:
Respiratory Medicine Case Reports

DOI:
[10.1016/j.rmedc.2011.08.006](https://doi.org/10.1016/j.rmedc.2011.08.006)

Publication date:
2012

Document version
Final published version

Document license
CC BY-NC-ND

Citation for pulished version (APA):
Christensen, A-S. H., & Johansen, I. S. (2012). A case of preventable pulmonary tuberculosis in a Greenlandic, heavily immune suppressed patient. *Respiratory Medicine Case Reports*, 5, 62-4.
<https://doi.org/10.1016/j.rmedc.2011.08.006>

Terms of use

This work is brought to you by the University of Southern Denmark through the SDU Research Portal. Unless otherwise specified it has been shared according to the terms for self-archiving. If no other license is stated, these terms apply:

- You may download this work for personal use only.
- You may not further distribute the material or use it for any profit-making activity or commercial gain
- You may freely distribute the URL identifying this open access version

If you believe that this document breaches copyright please contact us providing details and we will investigate your claim. Please direct all enquiries to puresupport@bib.sdu.dk



Case report

A case of preventable pulmonary tuberculosis in a Greenlandic, heavily immune suppressed patient

Anne-Sophie H. Christensen^{a,*}, Isik S. Johansen^b^a Department of Infectious Diseases, Copenhagen University Hospital, Rigshospitalet, Blegdamsvej 9, 2100 København Ø, Denmark^b Department of Infectious Diseases, Odense University Hospital, Odense, Denmark

ARTICLE INFO

Article history:

Received 18 August 2011

Accepted 19 August 2011

Keywords:

Tuberculosis
Rheumatoid arthritis
Biologics
Screening

ABSTRACT

Immune modulating therapy, such as tumour necrosis factor (TNF)-alpha inhibitors, is becoming increasingly more widespread in the treatment of many autoimmune diseases. One of the well-documented side effects of TNF-alpha inhibitors is an increased risk of reactivating latent tuberculosis infection (LTBI). Diagnostic tools available for diagnosing LTBI lack sensitivity and specificity. We report the case of a rheumatoid arthritis (RA) patient at high-risk of reactivation of LTBI, who should have been offered prophylactic anti-tuberculous treatment on two separate occasions: firstly, before initiating anti-TNF- α treatment and secondly, as part of routine tuberculosis contact tracing. He subsequently developed severe pulmonary tuberculosis and was hospitalised for 6 weeks.

© 2011 Elsevier Ltd. Open access under [CC BY-NC-ND license](http://creativecommons.org/licenses/by-nc-nd/3.0/).

1. Introduction

Biological drugs, including TNF- α inhibitors, play a crucial role in the treatment of many dermatologic, gastro-intestinal and rheumatologic autoimmune diseases – especially RA. It is well known that these drugs increase the risk of serious infections, in particular reactivation of LTBI as well as malignancies.^{1,2} The estimated incidence of LTBI in Danish patients undergoing anti-TNF- α treatment is 25/100,000 per year³; this equals a four-fold increase compared to the background incidence of 6/100,000 per year.⁴ In Denmark, following international guidelines,⁵ all patients are screened for LTBI before the initiation of immunomodulating drug therapy.

The traditional method for detecting LTBI, the tuberculin skin test (TST), has a lower sensitivity in patients receiving corticosteroids,⁶ and the specificity is dependant of the bacilli Calmette-Guerin (BCG) vaccination status of the patient.

The Mycobacterium tuberculosis-specific interferon- γ release assays (IGRA) have proven superior to the TST in having a higher specificity in BCG vaccinated patients and a slightly higher sensitivity generally – even in immune compromised hosts there are generally more responses to IGRA compared to TST.⁷ Despite its higher sensitivity, there is still a risk of false negative or inconclusive test results, especially in patients undergoing

immunosuppressive treatment. Recent studies have shown that corticosteroid treatment on its own lowers the sensitivity of IGRAs significantly^{8,9} – this poses a challenge when screening RA patients before initiating TNF- α treatment, because almost all these patients are already being treated with corticosteroids, such as prednisolone (PSL).

This case report aims to illustrate the importance of conducting a full risk-assessment in the pre-anti-TNF- α -therapy screening and not relying on a negative or inconclusive IGRA result to rule out LTBI. A thorough evaluation of risk factors such as ethnicity, age, current medications and recent exposure to TB is essential. This information must then be further assessed along with the results of currently available diagnostic tools for LTBI – the TST (in non-BCG vaccinated patients) and IGRA – and finally, chest X-ray.

2. Case report

A 45-year old male of Greenlandic origin was admitted to the acute medical ward at a university hospital in Copenhagen in May 2010 with a productive cough, weight loss and general malaise of one-week duration. He had a medical history of severe seronegative RA and Bechterew's disease, and was being treated with PSL 5 mg daily, Methotrexate (MTX) 12.5 mg weekly and Infliximab (INF) infusions every 8 weeks.

The patient was born and raised in Greenland, had moved to Denmark 13 years ago, and socialised within the Greenlandic community in Copenhagen. The patient had previously been

* Corresponding author. Tel.: +45 21454130; fax: +45 35456648.

E-mail address: annesophiechristensen@gmail.com (A.-S.H. Christensen).

known to have an alcohol abuse, but denied any current drug or substance abuse.

Vital parameters upon admission showed a normal blood pressure (119/80), a respiratory rate of 14, tachycardia (pulse 90) and subfebrility (temp. 37.7 °C). Clinical examination revealed pallor and cold sweating. Chest examination revealed a dampened percussion over the basal right lung field with reduced breath sounds upon auscultation. Abdominal examination found epigastric tenderness.

Routine laboratory investigations revealed elevated leucocytes 10.3 (reference: 3.0–9.0), thrombocytosis of 522 (reference: 140–340), sodium 130 (reference: 136–146) and CRP 241 (reference: <10). Chest X-ray found a right-sided basal infiltrate and pleural effusion (see Fig. 1A and B).

A tentative diagnosis of bacterial pneumonia was made and intravenous Cefuroxime treatment was initiated. Sputum and blood cultures were later found negative for bacteria and fungi. Direct microscopy of sputum and pleural fluid were both found negative for *Mycobacterium tuberculosis* complex.

In the following days the patient's clinical condition deteriorated with tachypnoea (respiratory rate 35–40), rising body temperature (39–40 °C) and sinus-tachycardia (rate 100–120). Medication was altered to intravenous Meropenem.

One-week later, another sputum test was analysed for *M. tuberculosis*; this was also microscopy negative, but was found positive using nucleic acid amplification (NAA) testing. A gastric lavage fluid sample was at the same time also found positive both through direct microscopy and NAA testing. Anti-tuberculous treatment was started immediately. The sputum sample revealed growth of fully sensitive *M. tuberculosis* after several weeks' culture. The patient recovered slowly and was discharged after three weeks. Two days later, the patient was re-hospitalised in a weakened, febrile state and with radiological progression of residual pleural effusion; he was discharged after three weeks.

Prior to initiating INF treatment in September 2009, the outpatient rheumatology clinic that followed the patient had tested him for LTBI using TST, chest X-ray and QFT. The TST was negative and the chest X-ray showed, according to the radiologist, apical unilateral chronic calcifications; the x-ray is in the patient file described as 'normal'. QFT was inconclusive and the department

had not followed the recommendation of repeating the test. It had not been noted in the medical record whether or not the patient was BCG vaccinated – in later entries from the infectious disease departments, it is however noted that the patient *had* a BCG scar.

Throughout the course of the first week of admission, it was discovered that in March 2010, the patient had been tested for TB as a routine part of contact tracing, due to recent contact with a newly diagnosed pulmonary TB index patient. A chest X-ray at the time revealed chronic pulmonary changes and the Quantiferon Gold in tube (QFT) test was negative. The department in charge of contact tracing claims not to have any knowledge of neither the patient's rheumatologic disease nor current medication. At the time of testing, the patient was taking three different types of immunosuppressive treatment: PSL, MTX, INF.

The patient has now completed the follow-up program at an infectious disease outpatient clinic and has received a total of 9 months of anti-tuberculous treatment; the reason for choosing a longer regime was partly that INF infusions were continued during the anti-tuberculous treatment and partly due to compliance issues.

3. Discussion

The above case illustrates a patient who, in two separate instances, should have been offered prophylactic anti-tuberculous chemotherapy: firstly, prior to starting INF treatment and secondly, through contact tracing.

At time of LTBI screening prior to INF treatment, the patient was already receiving two types of immunosuppressive medication – PSL and MTX. It has been shown, that PSL treatment lowers the sensitivity of IGRAs and must therefore be interpreted with care; in this case, the QFT was inconclusive and should have been repeated. The TST is ultimately useless, since the patient was BCG vaccinated. At this point the patient had a total of three risk factors relating to an increased risk of LTBI: firstly, the patient was born and raised in Greenland, a country of high TB-endemicity; in 2009, an incidence of 112/100,000 was reported,¹⁰ and this must be viewed in comparison with the significantly lower TB incidence in Denmark of 6/100,000.⁴ Secondly, he was undergoing immunosuppressive treatment; thirdly the chest x-ray showed apical calcifications that

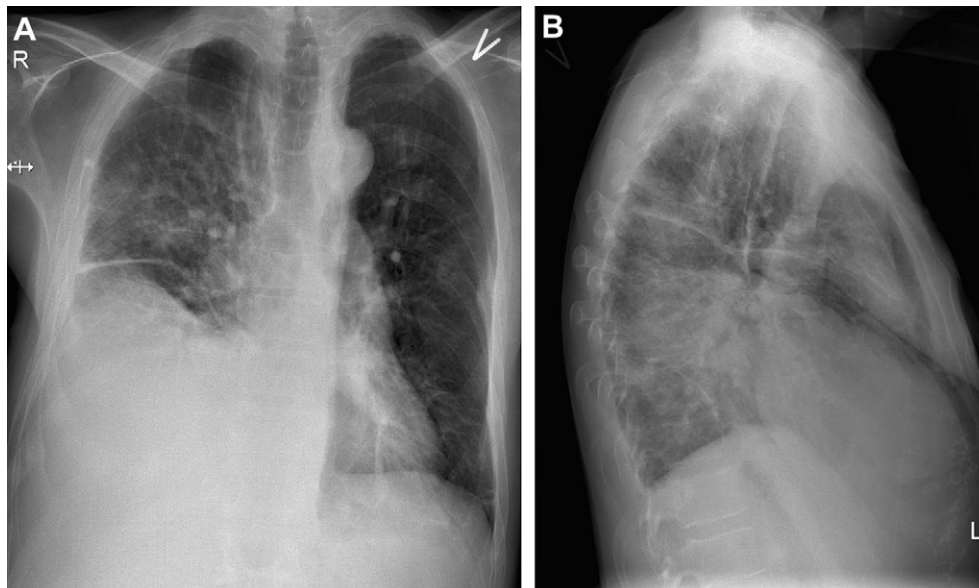


Fig. 1. 1A and 1B. Chest X-ray (frontal and lateral view) taken at time of primary admission showing right-sided basal infiltrate and pleural effusion.

could be related to previous TB-infection. These three risk factors combined should, in the authors' opinions, have resulted in prophylactic anti-tuberculous chemotherapy. According to Danish recommendations, the patient would have been eligible for prophylaxis just by being an immigrant from a country of high tuberculosis endemicity (incidence over 50/100,000).³

At the time of contact tracing, the patient had added yet another two risk factors to the ones mentioned above: he had initiated INF treatment and he had been in close contact with a recently diagnosed and contagious pulmonary TB index patient. A thorough interview with the patient would have revealed these important risk factors and would have resulted in prophylactic anti-tuberculous chemotherapy – regardless of the negative QFT result.

In conclusion, the above case could have been prevented through a systematic risk-assessment performed by the clinicians at both departments involved. None of the diagnostic tools available for diagnosing LTBI are 100% sensitive and must therefore be used in conjunction with an overall risk stratification. QFT test results must be interpreted with caution in a patient who is in an immunosuppressive state. It could be suggested that certain high-risk individuals, such as this Greenlandic RA patient, should be tested for LTBI and/or active TB before initiating any form of immune modulating therapy, even PSL.

Conflicts of interest

The authors have no conflicts of interest to declare in relation to this work.

References

1. Bongartz T, Sutton AJ, Sweeting MJ, Buchan I, Matteson EL, Montori V. Anti-TNF antibody therapy in rheumatoid arthritis and the risk of serious infections and malignancies: systematic review and meta-analysis of rare harmful effects in randomized controlled trials. *JAMA* 2006 May 17; **295**:2275–85.
2. Keane J, Gershon S, Wise RP, et al. Tuberculosis associated with Infliximab, a tumor necrosis factor alpha-neutralizing agent. *N Engl J Med* 2001; **345**: 1098–104.
3. Ravn P. Screening for tuberkuloseinfektion før behandling med biologiske lægemidler. [Screening for tuberculosis infection prior to medical therapy]. *Danish Ugeskr Laeger* 2011; **173**:893–6.
4. Statens Serum Institut, Department of Epidemiology Tuberculosis 2009 part 1. *Epi News* 2010; **Week 49**.
5. British Thoracic Society Standards of Care Committee. BTS recommendations for assessing risk and for managing Mycobacterium tuberculosis infection and disease in patients due to start anti-TNF- α treatment. *Thorax* 2005; **60**:800–5.
6. Murakami S, Takeno M, Kirino Y, et al. Screening of tuberculosis by interferon- γ release assay before biologic therapy for rheumatoid arthritis. *Tuberculosis (Edinb)* 2009 Mar; **89**:136–41.
7. Lange C, Mori T. Advances in the diagnosis of tuberculosis. *Respirology* 2010 Feb; **15**:220–40.
8. Soborg B, Ruhwald M, Hetland ML, et al. Comparison of screening procedures for Mycobacterium tuberculosis infection among patients with inflammatory diseases. *J Rheumatol* 2009; **36**:1876–84.
9. B elard E, Semb S, Ruhwald M, et al. Prednisolone treatment affects the performance of the QuantiFERON Gold In-Tube Test and the Tuberculin Skin Test in patients with autoimmune disorders screened for latent tuberculosis infection. *Inflamm Bowel Dis*; 2011 Feb 11. doi:10.1002/ibd.21605.
10. World Health Organisation. *Tuberculosis control in Greenland*. http://www.euro.who.int/_data/assets/pdf_file/0010/133489/e94755.pdf [accessed 20.06.2011].