

Bone structure in two adult subjects with impaired minor spliceosome function resulting from RNU4ATAC mutations causing microcephalic osteodysplastic primordial dwarfism type 1 (MOPD1)

Krøigård, Anne Bruun; Frost, Morten; Larsen, Martin Jakob; Ousager, Lilian Bomme; Frederiksen, Anja Lisbeth

Published in:
Bone

DOI:
[10.1016/j.bone.2016.08.023](https://doi.org/10.1016/j.bone.2016.08.023)

Publication date:
2016

Document version
Final published version

Document license
CC BY-NC-ND

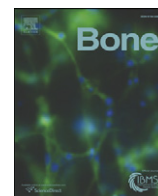
Citation for published version (APA):
Krøigård, A. B., Frost, M., Larsen, M. J., Ousager, L. B., & Frederiksen, A. L. (2016). Bone structure in two adult subjects with impaired minor spliceosome function resulting from RNU4ATAC mutations causing microcephalic osteodysplastic primordial dwarfism type 1 (MOPD1). *Bone*, 92, 145-149. <https://doi.org/10.1016/j.bone.2016.08.023>

Terms of use

This work is brought to you by the University of Southern Denmark through the SDU Research Portal. Unless otherwise specified it has been shared according to the terms for self-archiving. If no other license is stated, these terms apply:

- You may download this work for personal use only.
- You may not further distribute the material or use it for any profit-making activity or commercial gain
- You may freely distribute the URL identifying this open access version

If you believe that this document breaches copyright please contact us providing details and we will investigate your claim. Please direct all enquiries to puresupport@bib.sdu.dk



Case Report

Bone structure in two adult subjects with impaired minor spliceosome function resulting from *RNU4ATAC* mutations causing microcephalic osteodysplastic primordial dwarfism type 1 (MOPD1)☆☆☆



Anne Bruun Krøigård MD, PhD^{a,*}, Morten Frost MD, PhD^b, Martin Jakob Larsen MD, PhD^a, Lilian Bomme Ousager MD, PhD^a, Anja Lisbeth Frederiksen MD, PhD^a

^a Dept. of Clinical Genetics, Odense University Hospital, Odense, Denmark

^b Dept. of Endocrinology, Odense University Hospital, Odense, Denmark

ARTICLE INFO

Article history:

Received 5 January 2016

Revised 22 August 2016

Accepted 30 August 2016

Available online 31 August 2016

Keywords:

MOPD1

Taybi-Linder syndrome

RNU4ATAC

Osteodysplasia

HR-pQCT

Minor spliceosome

ABSTRACT

Microcephalic osteodysplastic primordial dwarfism type 1 (MOPD1), or Taybi-Linder syndrome is characterized by distinctive skeletal dysplasia, severe intrauterine and postnatal growth retardation, microcephaly, dysmorphic features, and neurological malformations. It is an autosomal recessive disorder caused by homozygous or compound heterozygous mutations in the *RNU4ATAC* gene resulting in impaired function of the minor spliceosome. Here, we present the first report on bone morphology, bone density and bone microstructure in two adult MOPD1 patients and applied radiographs, dual energy X-ray absorptiometry, high-resolution peripheral quantitative computed tomography and biochemical evaluation.

The MOPD1 patients presented with short stature, low BMI but normal macroscopic bone configuration. Bone mineral density was low. Compared to Danish reference data, total bone area, cortical bone area, cortical thickness, total bone density, cortical bone density, trabecular bone density and trabecular bone volume per tissue volume (BV/TV) were all low. These findings may correlate to the short stature and low body weight of the MOPD1 patients. Our findings suggest that minor spliceosome malfunction may be associated with altered bone modelling.

© 2016 The Authors. Published by Elsevier Inc. This is an open access article under the CC BY-NC-ND license (<http://creativecommons.org/licenses/by-nc-nd/4.0/>).

1. Introduction

Microcephalic Osteodysplastic Primordial Dwarfism type I (MOPD1), or Taybi-Linder syndrome [1,2], presents with distinctive skeletal dysplasia, severe intrauterine and postnatal growth retardation, microcephaly, central nervous system abnormalities, cataract, facial dysmorphism, sparse thin hair and dry skin [3]. MOPD1 is caused by biallelic mutations in the *RNU4ATAC* gene encoding the small nuclear RNA (snRNA) U4atac. The patients often die in early childhood. At present, approximately 42 children with MOPD1 and ten different *RNU4ATAC* mutations have been reported [4]. Radiological findings in infants with MOPD1 include dysplasia of the osseous skeleton with cleft vertebral arches, horizontal acetabula and short and bowed long bones [5]. However, the MOPD1 phenotype of adults, including bone phenotype, is previously unreported.

Two splicing mechanisms are present in eukaryotic cells. While the majority of introns, U2-type introns, are removed by the major spliceosome, the human genome contains around 800 U12-type introns, spliced by the slower minor spliceosome [6]. The U12 introns are found in 563 genes, typically containing only a single U12-type intron, surrounded by U2-type introns [7] and the resulting gene products are involved in a broad variety of cellular functions as they are found, according to the U12 Intron Database [8].

The pathophysiological background of MOPD1 is impaired function of the minor spliceosome as the *RNU4ATAC* gene encodes the snRNA U4atac, one of five snRNAs constituting the minor spliceosome [9]. Functional assays show that mutations in *RNU4ATAC* reduce U12 dependent splicing activity by >90% [10].

In our clinic, two adult siblings were diagnosed with MOPD1. Their short height prompted us to study the bone morphology and microarchitecture in this rare condition in order to explore the role of minor spliceosome function in relation to bone structure. We applied dual energy X-ray absorptiometry (DXA) scans and high-resolution peripheral quantitative computed tomography (HR-QCT) and identified abnormal bone microstructure. Biochemical analyses were performed in order to exclude common conditions affecting bone metabolism.

☆ The authors declare no conflict of interest.

☆☆ The work is not supported by any grants.

* Corresponding author at: Dept. of Clinical Genetics, Odense University Hospital, Sdr. Boulevard 29, DK-5000 Odense C, Denmark.

E-mail address: Anne.kroegaard@rsyd.dk (A.B. Krøigård).

2. Patients and methods

2.1. Patient material

The two siblings, age 17 and 24 years, diagnosed with MOPD1 are the second and third child of healthy non-consanguineous Caucasian parents with an otherwise unremarkable family history. The family includes a 29 year old, unaffected sister. Both patients presented with pre- and postnatal growth retardation ($-4SD$), microcephaly, developmental delay, cataract, hearing loss and dysmorphic features and they did not report of any previous fractures. The siblings are the first subjects with MOPD1 reported to have survived into adult life [11].

The study was approved by The Ethic Committee, Region of Southern Denmark (Project ID: S-20130058) and participants gave signed informed consent.

2.2. Mutation analysis

Genomic DNA from the patients and the parents were analysed at the Institute of Genetics & Molecular Medicine, University of Edinburgh, UK [11]. The *RNU4ATAC* gene was screened by bidirectional Sanger sequencing and analyses were performed using Mutation Surveyor (Softgenetics Inc.). The findings were validated by bidirectional Sanger sequencing at the Department of Clinical Genetics, Odense University Hospital, using SeqMan Pro v.12.0, DNA Star.

2.3. Bone parameters and body composition

Radiographs of radius, ulna, tibia and fibula, and proximal femur were obtained in two projections. Areal bone mineral density (aBMD) was measured at the lumbar spine (L1–L4), total hip and the femoral neck using DXA (Hologic Discovery, Waltham, Massachusetts, USA). Z-scores and T-scores were calculated using the reference range provided by the manufacturer and the Third National Health and Nutrition Examination Survey reference [12]. Body fat per cents were evaluated by whole body scans.

A HR-pQCT system (XtremeCT, Scanco Medical AG, Brüttisellen, Switzerland) was used to assess bone geometry, volumetric bone mineral density (vBMD) and microarchitecture of the non-dominant distal radius and tibia. Measures of total, cortical and trabecular microarchitecture were computed using the standard manufacture software [13]. Standardized algorithms were used to separate the bone into cortical and trabecular compartments, calculate trabecular bone volume per tissue volume (BV/TV), trabecular number (Tb.N), trabecular thickness (Tb.Th), and trabecular spacing (Tb.Sp) as previously described [14]. Lastly, images were used as input in a finite element analysis (FEA) using software provided by the manufacturer (μ FE element analysis solver v.1.15, Scanco Medical, Brüttisellen, Switzerland) in order to estimate bone strength [15]. The manufacturer phantom was scanned daily for quality control (QRM, Möhrendorf, Germany).

2.4. Biochemical evaluation

Blood samples were collected at 8 am (not fasting) and biochemical evaluation, including measurements of bone turnover markers Procollagen Type 1 N-Terminal Propeptide (PNP1) and collagen type 1 cross-linked C-telopeptide (CTX), was performed with automated techniques in an accredited laboratory including use of liquid chromatography-mass spectrometry (LC-MS) technique, Architect c16000 (Abbott Diagnostics) and Cobas 4800 (Roche Molecular Diagnostics).

2.5. Candidate genes with U12 dependent splicing activity

Phenolyzer (<http://phenolyzer.usc.edu/>) and Phevor [16] software were applied to search for disease associated candidate genes among the 563 genes predicted to be affected by malfunction of the minor

spliceosome. The software tools use phenotype terms to weight genes by the chance of being associated with the specified phenotype. The following terms were used for input: postnatal growth retardation; growth retardation; dwarfism; dwarfism microcephalic osteodysplastic primordial dwarfism; microcephaly; intrauterine growth retardation; skeletal dysplasias; short stature; insulin like growth factor I deficiency (IGF-1).

3. Results

The MOPD1 patients were shown to be compound heterozygous for a n.40C > T nucleotide substitution and a 85 base tandem duplication (n.17_101dup) in *RNU4ATAC* (NR_023343.1) which results in an insertion of a 85 base pair long sequence in position n.101. The n.40C > T mutation is extremely rare in the background population (ExAC minor allele frequency $< 1 \times 10^{-4}$) and predicted to disrupt the 5' stem I loop of the snRNA U4atac as the n.40C is one of four bases stabilizing this essential loop [11]. The other mutation, a novel 85 base pair insertion in position n.101, is also predicted to have a major impact on conformation by destroying the 3' stem I loop (*in silico* predictions made by Protein Data Bank 3SIU and PyMol v.1.7 software). The parents were each heterozygous carriers for one of these mutations confirming a cis-configuration of the mutations in the patients. The father was carrier of the 85 base pair long tandem duplication at n.101 and the mother was carrier of the n.40C > T mutation.

The two cases with MOPD1, female and male, age 24 and 17 years, respectively, presented with short stature of 142 and 143 cm and body mass index of 18.3 and 16.1 (kg/m^2), for the female and male patient, respectively (Table 1). The MOPD1 patients had fat percent of 36.3% and 20.8% and a lean body mass of 23.07 kg and 25.92 kg for the female and male patient, respectively. The height and weight of the parents were within the normal range.

Radiographs of radius, ulna, femur and tibia showed normal bone morphology including normal metaphyses (Supplementary Figs. 1–4). Results of the bone DXA scans are summarized in Table 2. The MOPD1 patients had low total bone mineral density, and Z-scores varied between -2.0 and -3.3 SD and -3.3 and -3.7 SD in the female and male patient, respectively. The father, age 50, also had a low bone mineral density with T-scores of -2.0 SD in the lumbar spine, -2.8 SD in the femoral neck and -2.4 in the hip. The mother, age 46, had normal bone mineral density. HR-pQCT results from scans of radius and tibia revealed that both MOPD1 patients had low values of cortical bone area, cortical thickness, total bone density, cortical bone density, trabecular bone density and trabecular bone volume per tissue volume (BV/TV) compared to age- and gender matched normal material [17,18] (Table 3). Estimated bone strength in both tibia and radius showed significantly lower failure load in cases compared to age- and sex matched normal values. For the female MOPD1 patient the estimated failure load in radius and tibia were 2377 and 5166 N compared to a mean of 3993 and 10,923 N, respectively, in the normal population [17]. For the male MOPD1 patient, the estimated failure load in radius and tibia were 1879 and 6307 N compared to a mean of 3009 N and 7957 N, respectively, in the normal population [18].

Biochemical evaluations are shown in Table 4. Normal levels of parathyroid hormone and thyroid stimulating hormone were seen in all family members. The male patient had a high level of follicle stimulating

Table 1
Clinical findings.

	Female patient	Male patient	Mother	Father
Gender	F	M	F	M
Age (years)	24	17	46	50
Height (cm)	142	143	169	180
Weight (kg)	37.6	33.0	69.8	66.0
BMI (kg/m^2)	18.3	16.1	24.1	20.3

Table 2

Bone area, bone mineral content, bone density, Z- and T-scores evaluated by DXA in MOPD1 cases and family members.

DXA	Female patient	Male patient	Mother	Father
Lumbar spine (L1–L4), total area (cm ²)	44.07	47.64	63.55	72.51
Lumbar spine (L1–L4), total BMC (g)	35.87	31.18	61.09	62.98
Lumbar spine (L1–L4), total BMD (g/cm ²)	0.814	0.655	0.961	0.869
Lumbar spine (L1–L4), total BMD (T-score) SD	−2.1	−4.0	−0.8	−2.0
Lumbar spine (L1–L4), total BMD (Z-score) SD	−2.0	−3.7	−0.3	−1.7
Femur neck, area (cm ²)	4.53	4.86	4.95	6.03
Femur neck, total BMC (g)	2.19	2.58	3.81	3.34
Femur neck, total BMD (g/cm ²)	0.482	0.530	0.769	0.554
Femur neck, total BMD (T-score) SD	−3.3	−2.9	−0.7	−2.8
Femur neck, total BMD (Z-score) SD	−3.3	−3.4	−0.2	−2.0
Hip, total area (cm ²)	31.65	33.20	35.86	46.54
Hip, total BMC (g)	18.63	19.95	32.95	31.21
Hip, total BMD (g/cm ²)	0.589	0.601	0.919	0.671
Hip, total BMD (T-score) SD	−2.9	−2.9	−0.2	−2.4
Hip, total BMD (Z-score) SD	−2.9	−3.3	0.1	−2.1
Whole body scan, total BMC (g)	1301.34	1137.91	2232.78	3039.76
Whole body scan, total BMD (g/cm ²)	0.901	0.825	1.081	1.364
Whole body scan, lean body mass (g)	23,073.5	25,922.2	45,371.4	54,144.2
Whole body scan, % fat (%)	36.3	20.8	33.1	15.5

BMC: bone mineral content. BMD: bone mineral density.

Table 3

Geometry, volumetric bone mineral density, microarchitecture, estimated bone strength and Finite Element Analysis failure load evaluated by HR-QCT in the MOPD1 cases and family members.

	Female patient	Male patient	Mother	Father
Radius				
Total bone area (mm ²)	267.9	252.8	295.6	460.9
Cortical bone area (mm ²)	30.0	15.4	57.1	63.8
Cortical thickness (mm)	0.53	0.47	0.82	0.76
Total bone density (mg/cm ³)	194.4	174.1	283.1	237.3
Cortical bone density (mg/cm ³)	796.8	599.3	920.6	821.9
Trabecular bone density (mg/cm ³)	103.3	116.0	129.1	137.7
Trabecular BV/TV (%)	8.6	9.6	10.7	11.4
Trabecular bone area (mm ²)	231.5	222.4	235.5	390.0
Trabecular number (mm ^{−1})	1.71	1.81	1.91	1.71
Trabecular thickness (mm)	0.050	0.053	0.056	0.066
Trabecular spacing (mm)	0.533	0.497	0.467	0.515
Cortical porosity (%)	0.26	1.77	0.78	2.25
Stiffness (kN/mm)	46.4	35.6	71.9	96.1
FEA failure load (N)	2377	1879	3738	4855
Tibia				
Total bone area (mm ²)	595.6	610.4	708.3	1048.5
Cortical bone area (mm ²)	60.8	78.9	112.6	101.0
Cortical thickness (mm)	0.68	0.95	1.06	0.92
Total bone density (mg/cm ³)	178.9	184.8	310.6	169.6
Cortical bone density (mg/cm ³)	856.7	803.0	914.2	784.5
Trabecular bone density (mg/cm ³)	97.3	84.0	200.1	96.4
Trabecular BV/TV (%)	8.1	7.0	16.6	8.0
Trabecular bone area (mm ²)	531.5	527.9	593.3	937.9
Trabecular number (mm ^{−1})	1.89	1.26	2.25	1.43
Trabecular thickness (mm)	0.042	0.055	0.074	0.056
Trabecular spacing (mm)	0.484	0.743	0.369	0.641
Cortical porosity (%)	0.82	0.59	2.71	7.55
Stiffness (kN/mm)	97.8	122.3	210.8	177.2
FEA failure load (N)	5166	6307	10,650	9165

BV/TV: bone volume per tissue volume. FEA: finite element analysis. N: Newton.

hormone (FSH), but normal levels of luteinizing hormone (LH) and testosterone. Both MOPD1 patients had very low levels of IGF-1 with values of 39 µg/L and 78 µg/L in the female and male patient, respectively. Normal levels of IGF-1 were observed in both patients in childhood. High levels of the bone turnover markers, with a serum type 1 procollagen (P1NP) of 352 µg/L (normal range 15–80 µg/L) and carboxy-terminal collagen crosslinks (CTX) of 1.08 µg/L (normal range 0.17–0.6 µg/L) [19] were seen in the male patient.

Result of search for MOPD1-associated gene products among the 563 genes containing U12-type introns can be found in Supplementary Table 1. Some genes, exemplified by the *OCRL* gene, associated with Lowe Syndrome [20], the *MATN3* gene, involved in spondyloepimetaphyseal dysplasia [21] and *BRAF* and *RAF1* associated with Leopard Syndrome [22] contain U12-type introns and are known to be involved in bone metabolism or growth retardation.

4. Discussion

To the best of our knowledge, this represents the first clinical description of bone morphology and structure in adult subjects with MOPD1. Radiographs showed normal macroscopic bone configuration while infant MOPD1 patients typically present with macroscopic skeletal dysplasia [23]. However, DXA scans showed that both MOPD1 patients had low bone mass. For both MOPD1 patients, the HR-pQCT parameters were substantially lower compared to the population based normal bone parameters of young adults [17,18].

The biochemical evaluation established that the low bone mass in the two MOPD1 patients result from neither vitamin D deficiency nor hyperthyroidism. However, we did observe low levels of IGF-1 in both patients. The patients declined formal testing of growth hormone deficiency in adulthood and treatment with GH was not initiated. Low level of IGF-1 may result from a low level of growth hormone (GH) but several factors such as the nutritional status is known to affect the IGF-1 level [24]. Although the body weight of both cases was low, there was no suspicion of malnutrition. GH and IGF-1 are the main stimulators of longitudinal bone growth and are also important for the acquisition of bone mass during the pre-pubertal period [25]. Importantly, normal levels of IGF-1 were observed in both patients in childhood (measured at age 1 and 10 years for the female patient and at age 1 year for the male patient compared to age- and gender matched normal material [26]). Though low levels of IGF-1 was observed in the adult patients this may not be a hallmark of the MOPD1 phenotype and is most likely not alone causative of the growth restriction. The male patient presented with high levels of P1NP and CTX, indicating high bone turnover. This is however, frequently observed in males younger than 25 years, [19] most likely indicating that bone growth may not have been finalized rather than abnormal bone metabolism. FSH was above the normal range in the male case, but the testosterone level was above normal ruling out hypogonadism as the cause of low bone mass. Regrettably, reassessments of gonadotropins were not performed.

Our findings may suggest that malfunction of the minor spliceosome could affect bone growth, accrual of bone mineral density in childhood causing lower peak bone mass and possibly even bone metabolism in adulthood. However, osteoporosis has also been described in patients with achondroplasia [27], the most common form of human dwarfism. In addition, factors like weight, height, age and physical activity highly influence bone strength [28]. The MOPD1 patients have a low body weight and relatively low level of physical activity. The relatively high fat percent, compared to age- and gender matched normal material [29] and the low muscle mass found in the MOPD1 patients most likely, at least to some extent, result from physical inactivity.

The fact that the father had low bone mass [30] entails that the abnormal DXA scan results in the siblings cannot unequivocally be concluded to result from altered expression of gene products spliced by the minor spliceosome as the siblings may be genetically predisposed

Table 4
Biochemical evaluation of MOPD1 cases and family members.

	Female patient	Male patient	Mother	Father
P1NP (15–80 µg/L)	63 µg/L	352 µg/L*	40 µg/L	28 µg/L
CTX (0.17–0.6 µg/L)	0.41 µg/L	1.08 µg/L*	0.30 µg/L	0.26 µg/L
25-OH Vitamin D (50–160 nmol/L)	63 nmol/L	177 nmol/L*	Na	Na
PTH (1.1–6.9 pmol/L)	2.8 pmol/L	5.2 pmol/L	3.7 pmol/L	3.8 pmol/L
TSH (0.5–4.3 10 ⁻³ IU/L)	3.9 · 10 ⁻³ IU/L	4.1 · 10 ⁻³ IU/L	1.2 10 ⁻³ U/L	1.0 · 10 ⁻³ U/L
Thyroxine (T ₄) (60–130 nmol/L)	Na	87 nmol/L	Na	Na
FSH (1.1–7.9 IU/L)	5.2 IU/L	21 IU/L	Na	Na
LH (1.5–11 IU/L)	2.4 IU/L	8.0 IU/L	Na	Na
Prolactin (2–14 µg/L)	10 µg/L	7 µg/L	Na	Na
Estradiol (0.24–2.4 nmol/L)	0.31 nmol/L	Na	Na	Na
Testosterone (8.40–30.0 nmol/L)	Na	30.8 nmol/L*	Na	Na
Prolactin (2–14 µg/L)	10 µg/L	7 µg/L	Na	Na
Cortisol (200–700 nmol/L)	238 nmol/L	266 nmol/L	Na	Na
Corticotrophin (ACTH) (2–14 pmol/L)	3 pmol/L	5 pmol/L	Na	Na
IGF-1 (females age 20–29, 188 µg/L [37]; males age 15–18 years, 135–835 µg/L)	39 µg/L*	78 µg/L*	Na	Na

P1NP: procollagen type 1 N-terminal propeptide. CTX: C-terminal cross-linking telopeptide of type I collagen. PTH: parathyroid hormone. TSH: thyroid stimulating hormone. T₄: thyroxine. FSH: follicle stimulating hormone. LH: luteinizing hormone. IGF-1: insulin-like growth factor 1. Na: not evaluated. * depicts an abnormal value.

via polygene inheritance to low bone mineral density [31,32]. Importantly, secondary causes of low bone mass were not observed in the father, suggesting that cases may be genetically predisposed to osteoporosis as well.

A weakness of the study is that measures of parameters including lean body mass, bone cortical structure and bone mineral density are confounded by the short stature of the patients. The low lean body mass may, for example actually be appropriate according to the low height of the patients. In addition to the challenges of interpretation of results, evaluations of patients that differ from the reference material also entail challenges on the technical side. The DXA scan technique is based on two dimensional images and systematically underestimates bone mineral density of smaller bones [33], confounding the bone mineral density measurements made on the MOPD1 patients. For the HR-pQCT measurements, the use of the standard method with measurements at a fixed distance from the distal endplate of tibia and radius, places the scan region further from the end plate in percentage of the entire bone length in the MOPD1 patients compared to the parents, which introduces a bias to the results. The use of a relative offset distance may have reduced this bias, however, the small body proportion would almost certainly influence the investigations irrespective of the method used to assess bone microarchitecture by HR-pQCT [34]. Iliac crest bone biopsies would have provided information on bone structure and metabolism, but neither of the cases consented to the procedures.

The two patients are compound heterozygous for two mutations in the *RNU4ATAC* gene, which encodes the snRNA U4atac, one of five snRNAs constituting the minor spliceosome. The mutations are positioned in the stem I loop of U4atac, which has been reported for other MOPD1 patients [11]. Both mutations are predicted to have a major functional impact on the snRNA. Thus, in the compound heterozygous state, minor spliceosome function is predicted to be impaired.

Increasing evidence suggests that malfunction of the minor spliceosome is causative of several recessive genetic disorders. Recently, compound heterozygote mutations in *RNU4ATAC*, although distinctive genomic positions from the MOPD1 related, have been shown to cause Roifman Syndrome, a rare congenital disorder characterized by pre- and postnatal growth retardation, antibody deficiency, skeletal abnormalities, retinal dystrophy, cognitive delay and dysmorphic features, which is phenotypically different than MOPD1 even though the genetic background is strikingly similar [35]. Most MOPD1 causal variants cluster in the stem I loop of U4atac snRNA, as is the case with our patients, while variants in the stem II seem to be specific to Roifman Syndrome indicating a genotype-phenotype association [35]. Thus, the exact genomic positions within the *RNU4ATAC* most likely influence to what extend transcription is affected. Biallelic mutations in the *RNPC3* gene, another gene encoding a protein involved in minor spliceosome function, was recently reported as a novel mechanism for isolated familial

GH hormone deficiency [36], thus entailing more limited phenotypic consequences.

Thus, the exact genomic positions within the *RNU4ATAC* most likely influence to what extend transcription is affected. Biallelic mutations in the *RNPC3* gene, another gene encoding a protein involved in minor spliceosome function, was recently reported as a novel mechanism for isolated familial growth hormone deficiency [36], thus entailing more limited phenotypic consequences.

No definitive conclusions can be drawn, but genes containing U12-type introns like *OCRL*, *MATN3*, *BRAF* or *RAF1*, where intragenic mutations are known to be associated with abnormal bone metabolism or growth retardation could be involved.

In summary, we report abnormal bone microstructure of adult MOPD1 patients and speculate that some of the gene products from the 563 genes containing U12-type introns are involved in bone metabolism or growth of statural height. Minor spliceosome function is not yet fully understood and functional studies are essential to elucidate the exact genotype-phenotype relations in diseases caused by mutations in genes involved in minor intron splicing.

Supplementary data to this article can be found online at <http://dx.doi.org/10.1016/j.bone.2016.08.023>.

Disclosures

All authors state that they have no conflict of interest.

Acknowledgements

The authors thank the family for participating in the study.

References

- [1] H. Taybi, D. Linder, Congenital familial dwarfism with cephaloskeletal dysplasia, *Radiol. Easton Pa.* 89 (1967) 275–281.
- [2] P. Meinecke, E. Passarge, Microcephalic osteodysplastic primordial dwarfism type I/III in sibs, *J. Med. Genet.* 28 (1991) 795–800.
- [3] R. Nagy, H. Wang, B. Albrecht, D. Wicczorek, G. Gillesen-Kaesbach, E. Haan, et al., Microcephalic osteodysplastic primordial dwarfism type I with biallelic mutations in the *RNU4ATAC* gene, *Clin. Genet.* 82 (2012) 140–146, <http://dx.doi.org/10.1111/j.1399-0004.2011.01756.x>.
- [4] P.D. Stenson, M. Mort, E.V. Ball, K. Shaw, A. Phillips, D.N. Cooper, The human gene mutation database: building a comprehensive mutation repository for clinical and molecular genetics, diagnostic testing and personalized genomic medicine, *Hum. Genet.* 133 (2014) 1–9, <http://dx.doi.org/10.1007/s00439-013-1358-4>.
- [5] S. Sigaudy, A. Toutain, A. Moncla, C. Fredouille, B. Bourlière, S. Ayme, et al., Microcephalic osteodysplastic primordial dwarfism Taybi-Linder type: report of four cases and review of the literature, *Am. J. Med. Genet.* 80 (1998) 16–24.
- [6] A. Levine, R. Durbin, A computational scan for U12-dependent introns in the human genome sequence, *Nucleic Acids Res.* 29 (2001) 4006–4013.
- [7] E.H. Niemelä, M.J. Frilander, Regulation of gene expression through inefficient splicing of U12-type introns, *RNA Biol.* 11 (2014) 1325–1329, <http://dx.doi.org/10.1080/15472626.2014.996454>.

- [8] T.S. Alioto, U12DB: a database of orthologous U12-type spliceosomal introns, *Nucleic Acids Res.* 35 (2007) D110–D115, <http://dx.doi.org/10.1093/nar/gkl796>.
- [9] P. Edery, C. Marcaillou, M. Sahbatou, A. Labalme, J. Chastang, R. Touraine, et al., Association of TALS developmental disorder with defect in minor splicing component U4atac snRNA, *Science* 332 (2011) 240–243, <http://dx.doi.org/10.1126/science.1202205>.
- [10] H. He, S. Liyanarachchi, K. Akagi, R. Nagy, J. Li, R.C. Dietrich, et al., Mutations in U4atac snRNA, a component of the minor spliceosome, in the developmental disorder MOPD 1, *Science* 332 (2011) 238–240, <http://dx.doi.org/10.1126/science.1200587>.
- [11] A.B. Krøigård, A. Jackson, E. Baple, K. Brusgaard, L.K. Hansen, L.B. Ousager, Two novel mutations in RNU4ATAC in two siblings with an atypical mild phenotype of microcephalic osteoplastic primordial dwarfism type 1 (MOPD1), *Clin. Dysmorphol* 25 (2016) 68–72.
- [12] J. Hanson, Standardization of femur BMD, *J. Bone Miner. Res. Off. J. Am. Soc. Bone Miner. Res.* 12 (1997) 1316–1317, <http://dx.doi.org/10.1359/jbmr.1997.12.8.1316>.
- [13] S. Boutroy, M.L. Bouxsein, F. Munoz, P.D. Delmas, In vivo assessment of trabecular bone microarchitecture by high-resolution peripheral quantitative computed tomography, *J. Clin. Endocrinol. Metab.* 90 (2005) 6508–6515, <http://dx.doi.org/10.1210/jc.2005-1258>.
- [14] A.L. Frederiksen, S. Hansen, K. Brixen, M. Frost, Increased cortical area and thickness in the distal radius in subjects with SHOX-gene mutation, *Bone* 69 (2014) 23–29, <http://dx.doi.org/10.1016/j.bone.2014.09.001>.
- [15] W. Pistoia, B. van Rietbergen, E.-M. Lochmüller, C.A. Lill, F. Eckstein, P. Ruegsegger, Estimation of distal radius failure load with micro-finite element analysis models based on three-dimensional peripheral quantitative computed tomography images, *Bone* 30 (2002) 842–848.
- [16] M.V. Singleton, S.L. Guthery, K.V. Voelkerding, K. Chen, B. Kennedy, R.L. Margraf, et al., Phevor combines multiple biomedical ontologies for accurate identification of disease-causing alleles in single individuals and small nuclear families, *Am. J. Hum. Genet.* 94 (2014) 599–610, <http://dx.doi.org/10.1016/j.ajhg.2014.03.010>.
- [17] S. Hansen, V. Shanbhogue, L. Folkestad, M.M.F. Nielsen, K. Brixen, Bone microarchitecture and estimated strength in 499 adult Danish women and men: a cross-sectional, population-based high-resolution peripheral quantitative computed tomographic study on peak bone structure, *Calcif. Tissue Int.* 94 (2014) 269–281, <http://dx.doi.org/10.1007/s00223-013-9808-5>.
- [18] L.A. Burt, H.M. Macdonald, D.A. Hanley, S.K. Boyd, Bone microarchitecture and strength of the radius and tibia in a reference population of young adults: an HR-pQCT study, *Arch. Osteoporos.* 9 (2014) 183, <http://dx.doi.org/10.1007/s11657-014-0183-2>.
- [19] N. Jenkins, M. Black, E. Paul, J.A. Pasco, M.A. Kotowicz, H.-G. Schneider, Age-related reference intervals for bone turnover markers from an Australian reference population, *Bone* 55 (2013) 271–276, <http://dx.doi.org/10.1016/j.bone.2013.04.003>.
- [20] S. Sharma, A. Skowronek, K.S. Erdmann, The role of the Lowe syndrome protein OCRL in the endocytic pathway, *Biol. Chem.* 396 (2015) 1293–1300, <http://dx.doi.org/10.1515/hsz-2015-0180>.
- [21] B. Isidor, L. Geffroy, B. de Courtivron, C. Le Caignec, C.T. Thiel, G. Mortier, et al., A new form of severe spondyloepimetaphyseal dysplasia: clinical and radiological characterization, *Am. J. Med. Genet. A* 161A (2013) 2645–2651, <http://dx.doi.org/10.1002/ajmg.a.36132>.
- [22] E. Martínez-Quintana, F. Rodríguez-González, LEOPARD syndrome: clinical features and gene mutations, *Mol. Syndromol.* 3 (2012) 145–157, <http://dx.doi.org/10.1159/000342251>.
- [23] G.M.H. Abdel-Salam, M.S. Abdel-Hamid, M. Issa, A. Magdy, A. El-Kotoury, K. Amr, Expanding the phenotypic and mutational spectrum in microcephalic osteodysplastic primordial dwarfism type I, *Am. J. Med. Genet. A* 158A (2012) 1455–1461, <http://dx.doi.org/10.1002/ajmg.a.35356>.
- [24] Z. Frysak, J. Schovaneck, M. Iacobone, D. Karasek, Insulin-like growth factors in a clinical setting: review of IGF-I, *Biomed. Pap. Med. Fac. Univ. Palacký Olomouc Czechoslov.* 159 (2015) 347–351, <http://dx.doi.org/10.5507/bp.2015.041>.
- [25] K.S. Shim, Pubertal growth and epiphyseal fusion, *Ann. Pediatr. Endocrinol. Metab.* 20 (2015) 8–12, <http://dx.doi.org/10.6065/apem.2015.20.1.8>.
- [26] B. Giwercman, A. Giwercman, K.W. Kastrop, N.E. Skakkebaek, Age- and sex-related variations in the serum concentration of somatomedin C in normal children and adults, *Ugeskr. Laeger.* 149 (1987) 1320–1323.
- [27] E.S. Arita, M.G.B. Pippa, M. Marcucci, R. Cardoso, A.R.G. Cortes, P.C.A. Watanabe, et al., Assessment of osteoporotic alterations in achondroplastic patients: a case series, *Clin. Rheumatol.* 32 (2013) 399–402, <http://dx.doi.org/10.1007/s10067-012-2126-x>.
- [28] F. Baptista, C. Barrigas, F. Vieira, H. Santa-Clara, P.M. Homens, I. Fragoso, et al., The role of lean body mass and physical activity in bone health in children, *J. Bone Miner. Metab.* 30 (2012) 100–108, <http://dx.doi.org/10.1007/s00774-011-0294-4>.
- [29] I. Larsson, L. Lissner, G. Samuelson, H. Fors, H. Lantz, I. Näslund, et al., Body composition through adult life: Swedish reference data on body composition, *Eur. J. Clin. Nutr.* 69 (2015) 837–842, <http://dx.doi.org/10.1038/ejcn.2014.268>.
- [30] NIH Consensus Development Panel on Osteoporosis Prevention, Diagnosis, and therapy, March 7–29, 2000: highlights of the conference, *South. Med. J.* 94 (2001) 569–573.
- [31] S. Ferrari, Human genetics of osteoporosis, *Best Pract. Res. Clin. Endocrinol. Metab.* 22 (2008) 723–735, <http://dx.doi.org/10.1016/j.beem.2008.08.007>.
- [32] G.-Y. Xu, Y. Qiu, H.-J. Mao, Common polymorphism in the LRP5 gene may increase the risk of bone fracture and osteoporosis, *Biomed. Res. Int.* 2014 (2014) 290531, <http://dx.doi.org/10.1155/2014/290531>.
- [33] B.S. Zemel, M.B. Leonard, A. Kelly, J.M. Lappe, V. Gilsanz, S. Oberfield, et al., Height adjustment in assessing dual energy X-ray absorptiometry measurements of bone mass and density in children, *J. Clin. Endocrinol. Metab.* 95 (2010) 1265–1273, <http://dx.doi.org/10.1210/jc.2009-2057>.
- [34] V.V. Shanbhogue, S. Hansen, U. Halekoh, K. Brixen, Use of relative vs fixed offset distance to define region of interest at the distal radius and tibia in high-resolution peripheral quantitative computed tomography, *J. Clin. Densitom. Off. J. Int. Soc. Clin. Densitom.* 18 (2015) 217–225, <http://dx.doi.org/10.1016/j.jocd.2014.12.002>.
- [35] D. Merico, M. Roifman, U. Braunschweig, R.K.C. Yuen, R. Alexandrova, A. Bates, et al., Compound heterozygous mutations in the noncoding RNU4ATAC cause Roifman syndrome by disrupting minor intron splicing, *Nat. Commun.* 6 (2015) 8718, <http://dx.doi.org/10.1038/ncomms9718>.
- [36] J. Argente, R. Flores, A. Gutiérrez-Arumí, B. Verma, G.Á. Martos-Moreno, I. Cuscó, et al., Defective minor spliceosome mRNA processing results in isolated familial growth hormone deficiency, *EMBO Mol. Med.* 6 (2014) 299–306, <http://dx.doi.org/10.1002/emmm.201303573>.
- [37] R. Kucera, O. Topolcan, L. Pecen, J. Kinkorova, S. Svobodova, J. Windrichova, et al., Reference values of IGF1, IGFBP3 and IGF1/IGFBP3 ratio in adult population in the Czech Republic, *Clin. Chim. Acta Int. J. Clin. Chem.* 444 (2015) 271–277, <http://dx.doi.org/10.1016/j.cca.2015.02.036>.