

Generalized and Naevoid Epidermolytic Ichthyosis in Denmark

Clinical and Mutational Findings

Bygum, Anette; Virtanen, Marie; Brandrup, Flemming; Gånemo, Agneta; Sommerlund, Mette; Strauss, Gitte; Vahlquist, Anders

Published in:
Acta Dermato-Venereologica

DOI:
10.2340/00015555-1447

Publication date:
2013

Document version:
Submitted manuscript

Citation for published version (APA):
Bygum, A., Virtanen, M., Brandrup, F., Gånemo, A., Sommerlund, M., Strauss, G., & Vahlquist, A. (2013). Generalized and Naevoid Epidermolytic Ichthyosis in Denmark: Clinical and Mutational Findings. *Acta Dermato-Venereologica*, 93(3), 309-313. <https://doi.org/10.2340/00015555-1447>

Go to publication entry in University of Southern Denmark's Research Portal

Terms of use

This work is brought to you by the University of Southern Denmark.
Unless otherwise specified it has been shared according to the terms for self-archiving.
If no other license is stated, these terms apply:

- You may download this work for personal use only.
- You may not further distribute the material or use it for any profit-making activity or commercial gain
- You may freely distribute the URL identifying this open access version

If you believe that this document breaches copyright please contact us providing details and we will investigate your claim.
Please direct all enquiries to puresupport@bib.sdu.dk

CLINICAL REPORT

Generalized and Naevoid Epidermolytic Ichthyosis in Denmark: Clinical and Mutational Findings*

Anette BYGUM¹, Marie VIRTANEN², Flemming BRANDRUP¹, Agneta GÅNEMO³, Mette SOMMERLUND⁴, Gitte STRAUSS⁵ and Anders VAHLQUIST²

¹Department of Dermatology and Allergy Centre, University Hospital, Odense, Denmark, ²Departments of Dermatology, University Hospital, Uppsala and

³Institute of Clinical Research in Malmö, Lund University, Skåne University Hospital, Malmö, Sweden, ⁴Department of Dermato-Venereology, Aarhus University Hospital, Aarhus and ⁵Department of Dermato-Allergology, University Hospital of Copenhagen, Hellerup, Denmark

A Danish–Swedish collaboration was established to identify and classify a Danish cohort of patients with epidermolytic ichthyosis, also known as epidermolytic hyperkeratosis. Patients were recruited from 5 dermatology departments in Denmark, and data were obtained using a structured questionnaire and a systematic examination together with photographs, histopathological descriptions and blood samples for mutational analysis. Sixteen patients from 12 families with generalized or naevoid epidermolytic ichthyosis and ichthyosis bullosa of Siemens were identified. Five families had mutations in K1 and 6 families had mutations in K10. Nine patients had been treated with systemic retinoids (etretinate, acitretin, isotretinoin or alitretinoin), but only 3 patients had acceptable treatment responses and chose to continue therapy. In conclusion epidermolytic ichthyosis is a rare disease with a prevalence of approximately 1 in 350,000 in Denmark and a high percentage of *de novo* mutations (75%). We identified 4 novel disease-causing mutations. *Key words: genomic DNA sequencing; epidermolytic ichthyosis; epidermolytic hyperkeratosis; phenotypic variation.*

(Accepted June 4, 2012.)

Acta Derm Venereol 2012; 92: XX–XX.

Anette Bygum, Department of Dermatology and Allergy Centre, Odense University Hospital, DK-5000 Odense C, Denmark. E-mail: anette.bygum@ouh.regionyddanmark.dk

Epidermolytic ichthyosis (EI; OMIM 113800), also referred to as epidermolytic hyperkeratosis or bullous congenital ichthyosiform erythroderma, is a rare keratinization disorder caused by dominant negative mutations in keratin genes *KRT1* and *KRT10*, leading to an unstable cytoskeleton of epithelial keratinocytes and epidermal hyperkeratosis (1). In contrast to most other ichthyoses, the histopathological picture of EI is distinctive, with hyperkeratosis, acanthosis and characteristic clumping

of tonofilaments, intracellular vacuolization and intra-epidermal blisters.

Children with generalized EI are usually born with erythroderma, extensive blistering and denuded skin that later changes into a more ichthyotic phenotype with rippled hyperkeratosis mainly on flexural surfaces. The bullous component gradually becomes less prominent, but patients may continuously have problems with blistering, especially after trauma or skin infections. In addition, some patients also have palmoplantar keratoderma (PPK).

The naevoid form of EI, linear epidermolytic ichthyosis (LEI), occurs as epidermal naevi with cytoskeletal abnormalities of epidermolytic hyperkeratosis representing somatic mosaicism. In case of gonadal mosaicism the offspring of the patient may develop full-blown EI. Therefore epidermolytic naevi are included in the most recent classification of keratinopathic ichthyosis (1).

Ichthyosis bullosa of Siemens (IBS) resembles EI, but has a milder phenotype with less hyperkeratosis, more superficial blistering and no PPK. Mutations in K2, a keratin expressed later during differentiation, cause IBS (1, 2).

In this study we describe the clinical subtypes and mutational findings in a cohort of 16 Danish patients with EI/IBS.

PATIENTS AND METHODS

Patients and samples

Patients were identified through a national study of congenital ichthyosis undertaken in 2004 to 2006 by 3 of the authors (AB, AG and FB). In order to trace all patients seen in Denmark from 1984 to 2003 with a diagnosis of congenital ichthyosis, contact was established with all 6 departments of dermatology. Patients with a clinical phenotype consistent with EI or IBS were included in this study.

Written informed consent was obtained from all patients according to approval by the Danish ethics committee (jr. no. VF20040178).

A complete medical history was obtained from all patients using a structured questionnaire. In order to obtain a uniform classification, patients were systematically examined by at least 2 of 3 authors (AB, AG and FB) together with a local dermatologist to give the best clinical classification. Photographs were taken, previous histopathological descriptions were reviewed

*The Editor-in-Chief has not had responsibility for this article; it has been handled fully by the Co-Editor, who made the decision to accept it.

and new skin biopsies for light or electron microscopy were taken in case of diagnostic doubt. Blood samples were obtained for DNA extraction and mutational analysis in *KRT1* and *KRT10*. In patients where no pathogenic mutation was identified, *KRT2* was also examined.

Genetic analyses

Genomic DNA (gDNA) was extracted from 2 ml ethylenediaminetetraacetic acid (EDTA) blood using E:Z:N:A:Midikit's (Omega Bio-Tek Norcross, GA, USA). 100 ng of gDNA was used for PCR amplification of all *KRT1* exons and the hot-spot regions in *KRT2* and *KRT10*. The DNA was added to a mix of 1×Taq buffer, 0.2 mM of each dNTP, forward and reverse primers (10 µM), 2.5 mM MgCl₂ and 0.05 U Taq polymerase (Applied Biosystems, Stockholm, Sweden) in a total volume of 50 µl.

All patients were initially screened for mutations in hotspot regions of *KRT1* and *KRT10* by denaturing high-performance liquid chromatography (HPLC) (Transgenomic, Omaha, USA). Before the analysis the PCR fragments were partially denatured by decreasing the temperature from 94°C to 40°C during 30 min. An aliquot of PCR fragments was purified by using GTXtm PCR DNA and GelBand purification Kit (GE Healthcare, Uppsala, Sweden) followed by DNA sequencing. Automated sequencing was done using Big Dye Terminator kit and analysed on an ABIPrism 377 DNA sequencer (Perkin-Elmer Applied Biosystems, Foster City, CA, USA).

RESULTS

A total of 16 patients from 12 families fulfilled the inclusion criteria for EI/IBS. The symptoms varied in intensity from mild to severe and in 8 of the patients an associated PPK was observed (Table I). For 2 families, 3 affected members were found in each family. In one of the families (number 5) an affected mother and 2 children with EI were found (Fig. 1), and in the other family (number 6) EI was observed in 3 generations, starting with a naevoid lesion in the grandfather (Fig. S1; available from: <http://www.medicaljournals.se/acta/content/?doi=10.2340/00015555-1447>).

Ten different disease-causing mutations were detected in 11 of the 12 families (Table I). Mutations in K1 were found in 5 families, and 6 families had mutations in K10. Six of these mutations have been described previously (3–8). The remaining mutations are novel: 3 point mutations with a non-conservative amino acid substitution (family numbers 1, 2 and 11) and 1 in-frame deletion of 30 bp in *KRT1* exon 2 (family number 5). Although a substitution of amino acid 486 in K1 has been described previously (9, 10), our family number 1 has a different point mutation, resulting in a different amino acid change in this position. The other 2 point mutations (family numbers 2 and 11) are located near previously reported disease-causing mutations in *KRT1* or *KRT10* (4, 11). In family number 5, an in-frame deletion in *KRT1* (p.His225_Phe234del) was found, which removes the last part of the L1 region and the beginning of region 1B of K1. There are no previous reports of such a mutation, but a point mutation causing

PPK has been described in this region (12). The mother in family number 5 was born with erythroderma and bullae and later developed rippled hyperkeratosis in the flexural areas (Fig. 1A). She had a persistent tendency to blistering and erosions on pressure-prone areas (Fig. 1B). She gave birth to 2 children with mild erythroderma and blistering at birth changing to more hyperkeratotic skin lesions within the first year of life. They all had white spongy soles and palms at birth (Fig. 1C), later developing into PPK.

We could not identify a mutation explaining the naevoid skin lesions in the father of patient IX with EI due to *KRT10* c.1333G>A. However, only blood leukocytes were available for analysis. Patient XVI, clinically and histopathologically diagnosed as IBS (Fig. S2; available from <http://www.medicaljournals.se/acta/content/?doi=10.2340/00015555-1447>), had no identifiable *KRT1*, *KRT2* or *KRT10* mutation, except for a previously reported polymorphism, an 18-bp deletion in exon 1 of *KRT2* (13).

DISCUSSION

We identified 16 Danish patients with generalized or naevoid EI and IBS, corresponding to a prevalence of approximately 1 in 350,000 in Denmark. This is 3 times higher than the estimated prevalence in other Scandinavian countries (14), but similar to prevalence estimates of 1 in 100,000–300,000 reported in the literature (15, 16).

The patients with generalized EI typically had disease onset from birth, with erythroderma and blisters with denuded skin areas (Fig. S3; available from: <http://www.medicaljournals.se/acta/content/?doi=10.2340/00015555-1447>). Some patients subsequently developed mild flexural involvement, while others had generalized erythroderma with blistering/erosion tendency continuing in adulthood, but overall symptoms improved with age. A few patients had very severe PPK with contractures (Fig. S4; available from <http://www.medicaljournals.se/acta/content/?doi=10.2340/00015555-1447>).

In this study, the percentage of *de novo* mutations was very high; 75% compared with a previously reported spontaneous mutation rate of about 50% (15–18). The majority of reported mutations were heterozygous missense mutations. When mutations are located at the conserved helix boundary motifs, the helix initiation or termination peptides and the non-helical H1 domain of K1 and K10, they will result in severe EI (17, 19). In family number 5 with a moderate EI phenotype, a partial deletion of L1 and 1B region in K1 was identified. Insertion/deletion mutations and splice site-defects or dinucleotide alterations in *KRT10* have also been described and more than 100 mutations in *KRT1* and *KRT10* have already been reported (17, www.interfil.org).

Table I. Summary of clinical and mutational data in 16 Danish patients with various types of epidermolytic ichthyosis (EI), showing those with *KRT1* mutations at the top (new mutations are shown in bold)

Pat. No. Diagnosis	Sex/age (years)	Familial (family No.)	Mutation	Protein	Clinical presentation		Histology showing EHK	
					At birth	At inclusion in study	LM	EM
I EI	M/34	No (1)	<i>KRT1</i> c.1457T>A	p.Leu486Gln	Blistering Erosions	Few erosions Hyperkeratosis PPK	Yes	Yes
II EI	M/20	No (2)	<i>KRT1</i> c.1424T>C	p.Leu475Pro ^a	Blistering Erosions	Focal blisters Hyperkeratosis PPK	Yes	ND
III EI	M/27	No (3)	<i>KRT1</i> c.1445A>G	p.Tyr482Cys	Erythroderma Blistering	Erythroderma Blistering Hyperkeratosis PPK	Yes	Yes
IV EI	M/40	No (4)	<i>KRT1</i> c.1465G>A	p.Glu489Lys	Blistering Erosions	Focal blisters EHK PPK	Yes	Yes
V EI	F/33	Yes (5)	<i>KRT1</i> c.673_702 del 30	p.His225_Phe 234del ^a	Erythroderma Blistering	Focal blisters Hyperkeratosis PPK	Yes	Yes
VI EI	M/3	Yes (5)	<i>KRT1</i> c.673_702 del 30	p.His225_Phe 234del	Erythroderma Blistering	Focal blisters Hyperkeratosis PPK	NT	NT
VII EI	F/1	Yes (5)	NT		Erythroderma Blistering	Erythroderma Blistering Hyperkeratosis PPK	NT	NT
VIII LEI	M/65	Yes (6)	No mutation found		Naevoid/striate thickening of skin on right-sided extremities	Striate Hyperkeratosis	Yes	NT
IX EI	F/38	Yes (6)	<i>KRT10</i> c.1333G>A	p.Glu445Lys	Erythroderma Erosions	Focal blisters Hyperkeratosis Erosions	Yes	NT
X EI	F/6	Yes (6)	NT		Erythroderma Erosions	Focal blisters EHK	NT	NT
XI EI	M/18	No (7)	<i>KRT10</i> c.466C>T	p.Arg156Cys	Erythroderma	Focal blisters Hyperkeratosis	Yes	Yes
XII EI	M/3	No (8)	<i>KRT10</i> c.466C>A	p.Arg156Ser ^b	Erythroderma Erosions	Focal blisters Hyperkeratosis	Yes	NT
XIII EI	F/44	No (9)	<i>KRT10</i> c.482T>C	p.Leu161Ser	Collodion baby	Focal blisters Hyperkeratosis PPK	Yes	NT
XIV EI	F/38	No (10)	<i>KRT10</i> c.482T>C	p.Leu161Ser ^c	Erosions	Focal erosions Hyperkeratosis	Yes	Yes
XV EI	M/42	No (11)	<i>KRT10</i> c.452A>C	p.Gln151Pro	Blistering Erosions	Erythroderma Blistering Hyperkeratosis	Yes	NT
XVI IBS	F/29	Adopted (12)	No mutation found		Unknown	Erythroderma Blistering Hyperkeratosis	Yes	NT

^aNo such mutation found in 50 controls.

^bAnalysed at the Department of Clinical Genetics, Aarhus University Hospital, Denmark.

^cAnalysed by Dr Paul Bowden, UWCM, Cardiff, UK.

EHK: epidermolytic hyperkeratosis; LM: light microscopy; EM: electron microscopy; LEI: linear epidermolytic ichthyosis; IBS: ichthyosis bullosa of Siemens; PPK: palmoplantar keratoderma; ND: not diagnostic; NT: not tested.

All 6 patients with K1 mutations had PPK, while only 1 out of 6 patients with K10 mutation had PPK. This is in accordance with earlier published studies (15, 17, 20). The absence of PPK in patients with mutation in K10 is explainable by palmoplantar expression of K9, which is a functional substitute for K10. In our study 2 unrelated females (patient XIII and XIV) had the same mutation in K10, but only one of them had a mild PPK,

suggesting that other genetic or environmental factors also influence the phenotype.

LEI is manifested as streaks of hyperkeratosis following the lines of Blaschko. LEI is caused by somatic mutations in K10, or rarely K1, arising post-zygotically during embryogenesis (21–23). Mutations have been demonstrated in keratinocytes from affected skin, whereas the mutations are absent in non-lesional skin and blood

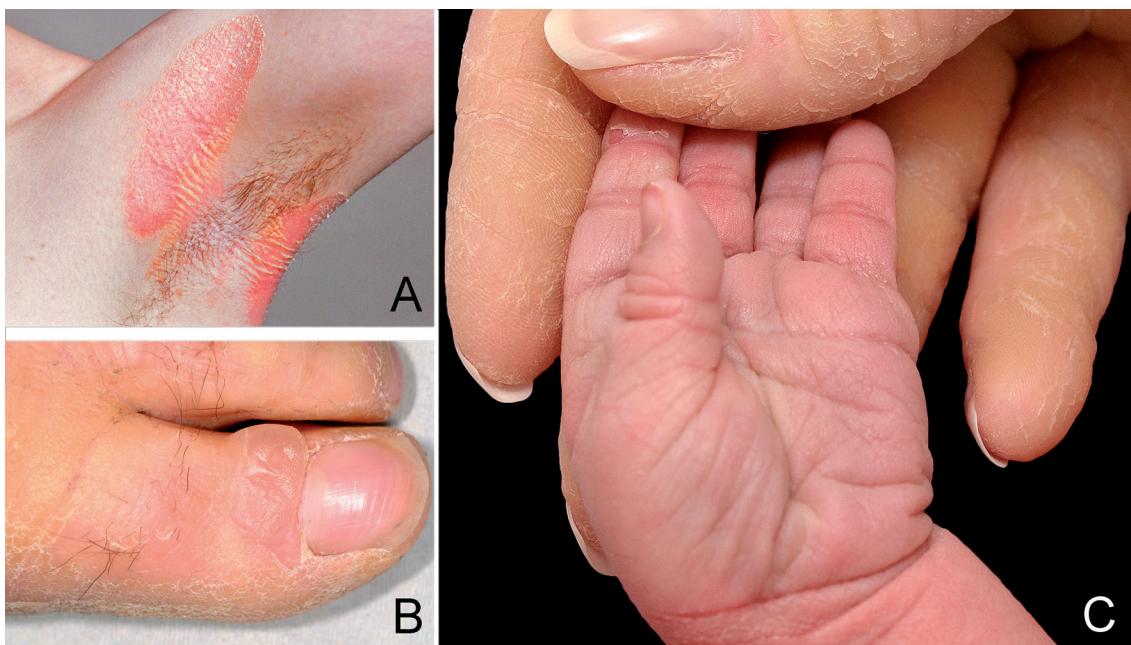


Fig. 1. (A) Epidermolytic ichthyosis with rippled hyperkeratosis in flexural area, and (B) tendency to blistering on pressure prone areas (patient V). (C) White spongy hands from birth in her daughter (patient VII); the mother's scaly fingers are also visible.

leukocytes (17). There seems to be a correlation between widespread LEI and the risk of germ-line transmission (22). The patient with LEI (VIII) had rippled and hyperkeratotic streaks on his right-side extremities, as well as thickened macerated skin in his right axilla (Fig. S1). Blood leukocytes, but no keratinocytes from affected skin, were available for molecular genetic analysis; no mutations in K1 or K10 could be detected.

We could not identify any mutation in patient XVI. The patient was adopted from Korea, and had clinical features of IBS (Fig. S2). Mutations outside the hotspot region of *KRT2* are possible.

The treatment options for EI are less than satisfactory. Retinoids are used in more severe cases of EI, but are usually moderately effective and carry a risk of side-effects when given systemically (24). Nine of our patients had been treated with systemic retinoids (etretinate, acitretin, isotretinoin or alitretinoin). Of these, 3 patients (patient I with K1 mutation and patients XIV and XV with K10 mutations) had acceptable treatment responses and are continuously on retinoid therapy. However, in another 2 patients (II and III) with K1 mutations skin symptoms such as blistering and erosions worsened during treatment; presumably they are more vulnerable to a retinoid down-regulation of K2, which may otherwise, to some extent, compensate for a mutated or missing K1 protein (14).

ACKNOWLEDGEMENTS

We wish to thank Johannes Kristensen for his help in arranging patient consultations at Bispebjerg Hospital. This study was supported by grants from Kgl. Hofbuntmager Aage Bangs Fond and from the Welander and Finsen Foundations.

The authors declare no conflicts of interest.

REFERENCES

- Oji V, Tadani G, Akiyama M, Bardon CB, Bodemer C, Bourrat E, et al. Revised nomenclature and classification of inherited ichthyoses: results of the first ichthyosis consensus conference in Sorèze 2009. *J Am Acad Dermatol* 2010; 63: 607–641.
- McLean WH, Morley SM, Lane EB, Eady RA, Griffiths WA, Paige DG, et al. Ichthyosis bullosa of Siemens – a disease involving keratin 2e. *J Invest Dermatol* 1994; 103: 277–281.
- Chassaing N, Kanitakis J, Sportich S, Cordier-Alex MP, Titeux M, Calvas P, et al. Generalized epidermolytic hyperkeratosis in two unrelated children from parents with localized linear form, and prenatal diagnosis. *J Invest Dermatol* 2006; 126: 2715–2717.
- Syder AJ, Yu QC, Paller AS, Giudice G, Pearson R, Fuchs E. Genetic mutations in the K1 and K10 genes of patients with epidermolytic hyperkeratosis. Correlation between location and disease severity. *J Clin Invest* 1994; 93: 1533–1542.
- Betlloch I, Lucas Costa A, Mataix J, Pérez-Crespo M, Balaster I. Bullous congenital ichthyosiform erythroderma: a sporadic case produced by a new *KRT10* gene mutation. *Pediatr Dermatol* 2009; 26: 489–491.
- Rothnagel JA, Dominey AM, Dempsey LD, Longley MA, Greenhalgh DA, Gagne TA, et al. Mutations in the rod domains of keratins 1 and 10 in epidermolytic hyperkeratosis. *Science* 1992; 257: 1128–1130.
- Rothnagel JA, Fisher MP, Axtell SM, Pittelkow MR, Anton-Lamprecht I, Huber M, et al. A mutational hot spot in keratin 10 (*KRT10*) in patients with epidermolytic hyperkeratosis. *Hum Mol Genet* 1993; 2: 2147–2150.
- McLean WH, Eady RA, Dopping-Hepenstal PJ, McMillan JR, Leigh IM, Navsaria HA, et al. Mutations in the rod 1A domain of keratins 1 and 10 in bullous congenital ichthyosiform erythroderma (BCIE). *J Invest Dermatol* 1994; 102: 24–30.

9. Lee DY, Ahn KS, Lee CH, Rho NK, Lee JH, Lee ES, et al. Two novel mutations in the keratin 1 gene in epidermolytic hyperkeratosis. *J Invest Dermatol* 2002; 119: 976–977.
10. Osawa R, Akiyama M, Izumi K, Ujiie H, Sakai K, Nemoto-Hasebe I, et al. Extremely severe palmoplantar hyperkeratosis in a generalized epidermolytic hyperkeratosis patient with a keratin 1 gene mutation. *J Am Acad Dermatol* 2011; 64: 991–993.
11. Sybert VP, Francis JS, Corden LD, Smith LT, Weaver M, Stephens K, et al. Cyclic ichthyosis with epidermolytic hyperkeratosis: a phenotype conferred by mutations in the 2B domain of keratin K1. *Am J Hum Genet* 1999; 64: 732–738.
12. Terron-Kwiatkowski A, van Steensel MA, van Geel M, Lane EB, McLean WH, Steijlen PM. Mutation S233L in the 1B domain of keratin 1 causes epidermolytic palmoplantar keratoderma with “tonotubular” keratin. *J Invest Dermatol* 2006; 126: 607–613.
13. Smith FJ, Maingi C, Covello SP, Higgins C, Schmidt M, Lane EB, et al. Genomic organization and fine mapping of the keratin 2e gene (KRT2E): K2e V1 domain polymorphism and novel mutations in ichthyosis bullosa of Siemens. *J Invest Dermatol* 1998; 111: 817–821.
14. Virtanen M, Gedde-Dahl T Jr, Mörk NJ, Leigh I, Bowden PE, Vahlquist A. Phenotypic/genotypic correlations in patients with epidermolytic hyperkeratosis and the effects of retinoid therapy on keratin expression. *Acta Derm Venereol* 2001; 81: 163–170.
15. DiGiovanna JJ, Bale SJ. Clinical heterogeneity in epidermolytic hyperkeratosis. *Arch Dermatol* 1994; 130: 1026–1035.
16. Bale SJ, Compton JG, DiGiovanna JJ. Epidermolytic hyperkeratosis. *Semin Dermatol* 1993; 12: 202–209.
17. Arin MJ, Oji V, Emmert S, Hausser I, Traupe H, Krieg T, et al. Expanding the keratin mutation database: novel and recurrent mutations and genotype-phenotype correlations in 28 patients with epidermolytic ichthyosis. *Br J Dermatol* 2011; 164: 442–447.
18. Kwak J, Maverakis E. Epidermolytic hyperkeratosis. *Dermatol Online J* 2006; 12: 6.
19. Porter RM, Lane EB. Phenotypes, genotypes and their contribution to understanding keratin function. *Trends Genet* 2003; 19: 278–285.
20. Virtanen M, Smith SK, Gedde-Dahl T Jr, Vahlquist A, Bowden PE. Splice site and deletion mutations in keratin (KRT1 and KRT10) genes: unusual phenotypic alterations in Scandinavian patients with epidermolytic hyperkeratosis. *J Invest Dermatol* 2003; 121: 1013–1020.
21. Nazzaro V, Ermacora E, Santucci B, Caputo R. Epidermolytic hyperkeratosis: generalized form in children from parents with systematized linear form. *Br J Dermatol* 1990; 122: 417–422.
22. Paller AS, Syder AJ, Chan YM, Yu QC, Hutton E, Tadini G, et al. Genetic and clinical mosaicism in a type of epidermal nevus. *N Engl J Med* 1994; 331: 1408–1415.
23. Tsubota A, Akiyama M, Sakai K, Goto M, Nomura Y, Ando S, et al. Keratin 1 gene mutation detected in epidermal nevus with epidermolytic hyperkeratosis. *J Invest Dermatol* 2007; 127: 1371–1374.
24. Vahlquist A, Gånemo A, Virtanen M. Congenital ichthyosis: an overview of current and emerging therapies. *Acta Derm Venereol* 2008; 88: 4–14.