

**Three cases of *Cutibacterium avidum* prosthetic valve infective endocarditis at a single heart center**

Nørskov-Lauritsen, Niels; Riber, Lars P.S.; Dzajic, Esad; Prangsgaard, Kenneth

*Published in:*  
International Journal of Infectious Diseases

*DOI:*  
10.1016/j.ijid.2024.107099

*Publication date:*  
2024

*Document version:*  
Final published version

*Document license:*  
CC BY-NC-ND

*Citation for pulished version (APA):*  
Nørskov-Lauritsen, N., Riber, L. P. S., Dzajic, E., & Prangsgaard, K. (2024). Three cases of *Cutibacterium avidum* prosthetic valve infective endocarditis at a single heart center. *International Journal of Infectious Diseases*, 146, Article 107099. <https://doi.org/10.1016/j.ijid.2024.107099>

Go to publication entry in University of Southern Denmark's Research Portal

**Terms of use**

This work is brought to you by the University of Southern Denmark.  
Unless otherwise specified it has been shared according to the terms for self-archiving.  
If no other license is stated, these terms apply:

- You may download this work for personal use only.
- You may not further distribute the material or use it for any profit-making activity or commercial gain
- You may freely distribute the URL identifying this open access version

If you believe that this document breaches copyright please contact us providing details and we will investigate your claim.  
Please direct all enquiries to [puresupport@bib.sdu.dk](mailto:puresupport@bib.sdu.dk)



## Short Communication

Three cases of *Cutibacterium avidum* prosthetic valve infective endocarditis at a single heart centerNiels Nørskov-Lauritsen<sup>1,\*</sup>, Lars P.S. Riber<sup>2</sup>, Esad Dzajic<sup>3</sup>, Kenneth Prangsgaard<sup>4</sup><sup>1</sup> Department of Clinical Microbiology, Odense University Hospital, Odense, Denmark<sup>2</sup> Department of Thoracic Surgery, Odense University Hospital, Odense, Denmark<sup>3</sup> Department of Clinical Microbiology, Esbjerg and Grindsted Hospital, Esbjerg, Denmark<sup>4</sup> Department of Cardiology, Odense University Hospital, Odense C, Denmark

## ARTICLE INFO

## Article history:

Received 1 March 2024

Revised 14 May 2024

Accepted 14 May 2024

## Keywords:

Innate microflora

*Cutibacterium/Propionibacterium*

Vigorous sampling

PCR deficits

Epidemiology

## ABSTRACT

**Objective:** To resolve an exceptional clustering of *Cutibacterium avidum* prosthetic valve infective endocarditis (IE) at a single heart center.**Methods:** During a period of 21 months, three patients experienced *C. avidum* bacteremia 24–128 days after aortic valve replacement. Operative procedures and electronic prescriptions of antimicrobials were surveyed, and bacterial isolates were genome sequenced.**Results:** The prosthetic valves were inserted by separate surgical teams. In one case, echocardiographic confirmation of IE was not achieved until 4 months after the first positive blood culture, but the causative agents were irrefutably documented in all cases by culture, or amplification of bacterial deoxyribonucleic acid, from removed prosthetic material. Whole-genome sequencing clustered isolates to a distinctive subgroup of the species but did not suggest inter-patient transmission of isolates.**Conclusions:** Despite vigorous sampling of blood and tissue, detection of *C. avidum* was not unconditional, neither by culture nor polymerase chain reaction test. The causative agent is likely underreported and should be meticulously searched for in culture-negative prosthetic valve endocarditis.

© 2024 The Authors. Published by Elsevier Ltd on behalf of International Society for Infectious Diseases.

This is an open access article under the CC BY-NC-ND license (<http://creativecommons.org/licenses/by-nc-nd/4.0/>)

## Introduction

The widespread use of implantable prosthetic material has increased the incidence of infective endocarditis (IE) and modified the spectrum of causative microorganisms. Foreign body surfaces constitute a distinct target for adherence, and *Cutibacterium acnes* now accounts for 6–10% of prosthetic IE cases [1]. *C. acnes* is a recognized agent of various prosthetic infections but reports of *Cutibacterium avidum* infections are not frequent [2]. A comprehensive list of *C. avidum* case reports up to 2018 is available [3], but only three cases of IE are included, all preceded by aortic valve replacement.

## Case series (see Figure 1)

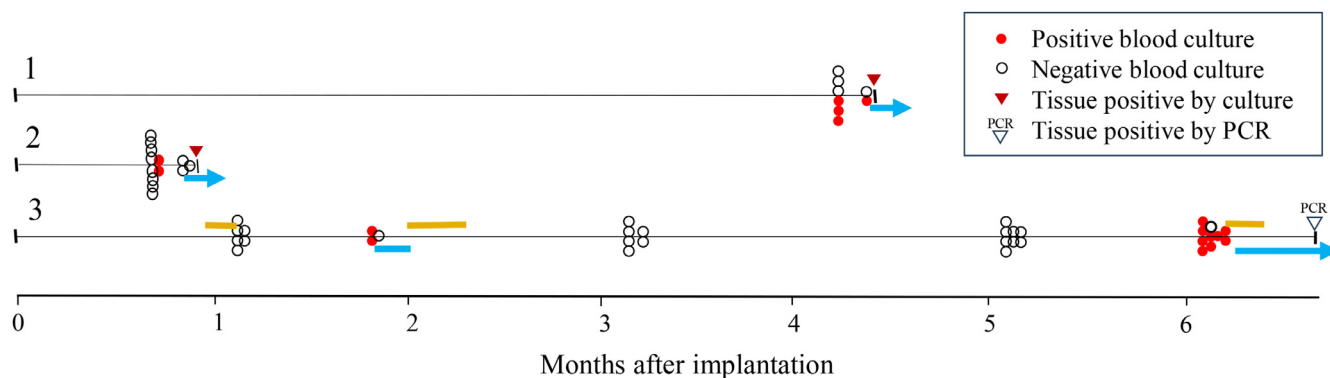
Case 1. Elective implantation of mechanical composite graft for severe aortic valve stenosis in an otherwise healthy 34-year-old female. Four months later the patient presented

with a history of fever for 2 weeks, elevated C-reactive protein (CRP) levels (48 mg/liter) and anemia (hemoglobin 5.4 mmol/liter). Transesophageal echocardiography (TEE) demonstrated aortic root abscess and vegetation on the mechanical valve, and the homograft was replaced with an aortic root bioprostheses.

Case 2. Elective implantation of mechanical valve for severe, but asymptomatic aortic valve stenosis in 66-year-old female with type 2 diabetes. Three weeks after discharge the patient was admitted with malaise, high fever, and elevated CRP. TEE showed inconclusive consolidation of the aortic root, and no visible excrescences on mechanical valves. CRP-levels dropped from 123 to 60 mg/liter without antimicrobial treatment. Three days later the patient was readmitted due to continuous fever. The last set of the original blood samples was now positive with Gram-positive rods. A TEE performed 5 days after the first revealed a distinct outgrowth from the tricuspid valve into the right atrium, possibly originating from an aortic root abscess *C. avidum* was cultured from removed heart tissue, mediastinal tissue, and prosthesis.

\* Corresponding author: Tel.: +45 6541 4795; fax: +45 6541 4785.

E-mail address: [niels.norskov-lauritsen@rsyd.dk](mailto:niels.norskov-lauritsen@rsyd.dk) (N. Nørskov-Lauritsen).



**Figure 1.** Collection of 54 blood samples partitioned into culture bottles FA plus and FN plus (BacT/ALERT bioMerieux, Sweden), and prescription of antimicrobial agents in consecutive time from implantation to replacement of prosthetic valves, IE (Infective Endocarditis) cases 1-3. Open circles represent negative cultures; red circles indicate culture of *C. avidum* in one or both of two collected vials. Isolates from case 1 were solely cultured in aerobic bottles (FA Plus); the two positive blood samples from case 2 were cultured in both vials; isolates from case 3 were cultured in both vials in three samples, and in anaerobic bottles (FN Plus) only in eight samples. Colored bars adjacent to timelines indicate prescribed antimicrobials (oral, above line; intravenous, below line). Bars with arrowheads indicate initiation of therapy directed against endocarditis. *C. avidum* was identified in tissue removed with prosthetic material (triangles).

Case 3. Elective implantation of both mitral- and aortic valves for stenoses in a 66-year-old female with hypertension, chronic obstructive pulmonary disease, and complete atrio-ventricular block. Four weeks after insertion, the general practitioner prescribed amoxicillin for treatment of dry cough and fever without convincing effect, and the patient was admitted to hospital. The patient had low grade fever (37.9°C) and elevated CRP (89 mg/liter). TEE showed atrial fibrillation, and anticoagulation therapy was initiated. Three weeks later, the patient was readmitted with fever (38.9°C), and intravenous piperacillin-tazobactam was initiated. When blood cultures of *C. avidum* 6 days later was communicated to the clinicians, the patient was already discharged with oral amoxicillin-clavulanate prescribed for 7 days. One and 3 months later, multiple blood cultures were negative. Six months after implantation, continuous *C. avidum* bacteremia was documented. The patient was subjected to valve exchange surgery, and *C. avidum* 16S ribosomal ribonucleic acid (rRNA) gene was polymerase chain reaction (PCR) amplified from aortic valve vegetations.

## Results and discussion

Three patients experienced bacteremia with *C. avidum* after insertion of prosthetic valves at a single heart center in Denmark. The bacteria were susceptible to penicillin according to European Committee on Antimicrobial Susceptibility Testing (EUCAST) Clinical Breakpoint Tables v. 13.1 guidelines for *C. acnes* (MIC ≤ 0.06 mg/liter), and 3-gram benzylpenicillin administered every 6 hours was prescribed, in addition to surgical replacement of prosthetic material.

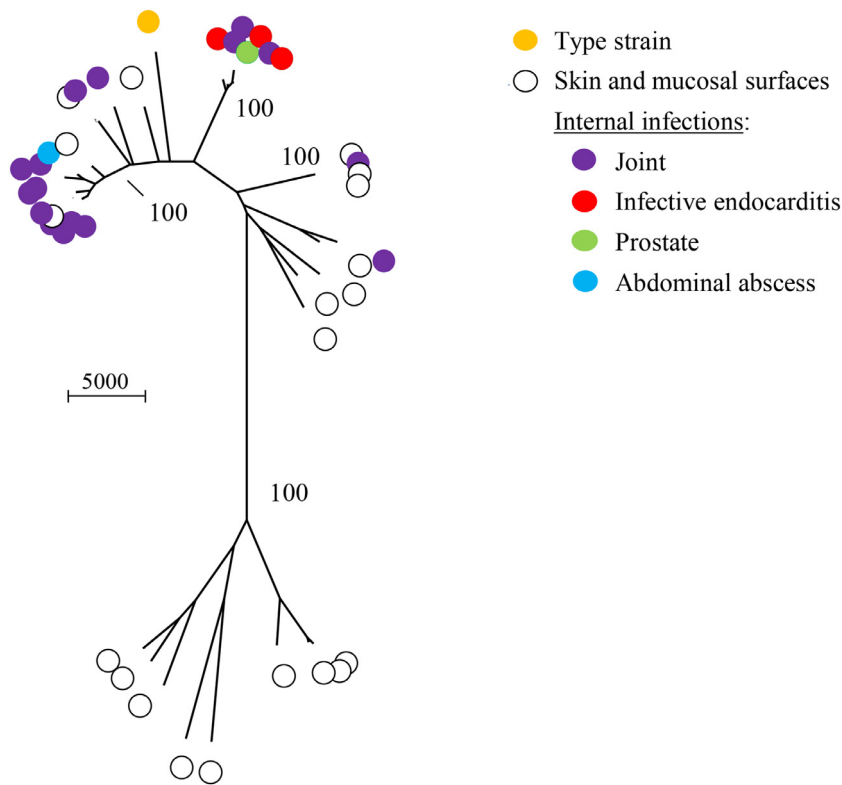
Insertion of the prosthetic valves were performed by three different surgical teams. Two bacterial genome sequences of case #3 cultured 130 days apart were identical (see below), suggesting a rapid inception of IE; however, the diagnosis was delayed in this case (Figure 1). We compared bacterial genomes from the three patients with genomes from the public repositories where details of culture site were given. The population structure of the species appears coherent, albeit with noticeable clusters. The endocarditis strains cluster with three strains from prosthetic joint infection plus the prostate strain (Figure 2). Isolates from case 2 and 3 were closely related, and we compared isolates from

these patients with two related sequences from GenBank. The limited comparison identified 2097 core genes shared by all five isolates. Only one SNP separated the two genome sequences of case 3, cultured 130 days apart. In contrast, 215 SNPs distinguished the isolate of case 3 from case 2, whereas 84 and 106 SNPs separated case 3 from GCF\_000463645.1 (prostate strain 2013) and GCF\_024104915.1 (prosthetic joint infection 2019), respectively. Thus, isolates of cases 2 and 3 were definitely discrete, and all three agents may originate from the microbiota of individual patients. The “IE cluster” of Figure 2 is conspicuous, but a specific set of known virulence genes did not complement the intriguing union of pathogenic strains in the IE cluster, which is defined by similarity of core genes.

The contrast of only three cases of *C. avidum* IE published in the literature vs three cases diagnosed within two years at a single heart center must be addressed. Several observations demonstrate the difficult identification of the pathogen in clinical samples from documented infections. Of 54 double-portion blood samples, 37 were negative despite limited administration of antibiotics at hospitals or prescription by general practitioners (Figure 1). The patient in case #2 rapidly presented with symptoms shortly after insertion of mechanical valve, but only the last of five double sets of blood cultures finally revealed the causative agent. Abundant colonies of *C. avidum* were, however, cultured from prosthetic material and aortic root tissue removed 30 h after initiation of antimicrobial therapy. This is in contrast to the single colonies cultured from prosthetic material removed the day after initiation of antimicrobial treatment from case #1 (tissue samples were negative). In case #3, prosthetic material removed was negative by PCR (Applied Biosystems™ Fast MicroSEQ™ 500 16S rDNA PCR Kit). Because of discord between PCR and macroscopic evidence from surgery, additional tissue material was selected from the removed prosthesis, and on the second attempt *C. avidum* 16S rRNA gene was amplified.

Blood culture-negative IE is common and may constitute up to 20% of cases [4]. It is well known that *C. acnes* is difficult to culture from prosthetic joint infections, and prolonged culture of such tissue is recommended [5,6]. Extended incubation of blood was recently evaluated for diagnosis in suspected cases of IE, but the outcome meager: only one detection of *C. acnes* was consistent with definite prosthetic aortic valve endocarditis, while the bacterium was cultured after prolonged incubation in 18 cases where suspected diagnosis of IE was ruled out [7].

The mean time to positive blood culture signal in our case series was 4.2 days (range 3.2–6.0 days). Our case series is small, and



**Figure 2.** Neighbor-joining dendrogram of three strains from infective endocarditis and one from abdominal empyema, plus 38 human strains from the public repositories. Evolutionary distances are based on base substitutions in 1333 core genes (1,378,035 nucleotides; 11-42,103 pairwise SNPs). Skin and mucosal samples comprise 13 samples from skin/acne/wound, six fecal or gut samples, and one vaginal sample. Whole-genome sequencing, annotation and identification of core genes were performed as described [9,10]. Selected bootstrap values are indicated. Bar represents 5000 residue substitutions. SNP, single nucleotide polymorphism.

the time-window cannot be directly compared to the 7-days median time to positive signal reported from 54 patients with bacteremia and *C. acnes* endocarditis [8]. Additionally, the indolent presentation of symptoms in that study, where most patients were admitted without prior experience of fever, and with a median CRP level of 36 mg/liter, does not mirror our case series. It cannot be excluded, that some blood culture vials deemed negative after 6 days of incubation (our time limit of incubation), could afterwards have presented growth of *C. avidum*. But the clustering of positive signals after 4-5 days does not indicate that prolonged incubation will markedly improve diagnosis of *C. avidum* IE. Lack of antimicrobial restraint can definitely obstruct identification, but experience from cases #2 and #3 testifies to the challenge of detection, despite definite IE and absence of recently prescribed antimicrobials. Current blood culture systems may lack competence to sustain growth of *C. avidum*, or the biofilm nature of the bacterium suppresses the frequency of detachment from the prosthesis.

**Conclusion**

A possible explanation is that *C. avidum* is a relatively common, but unrecognized cause of prosthetic valve IE. Blood cultures should be vigorously sampled before antimicrobials are prescribed. *Cutibacterium* species are considered anaerobes, but microbiologists should be aware that *C. avidum* may preferentially be recovered from aerobic incubation. If surgical removal of infected prosthesis is performed, the material provides an opportunity for identification after antimicrobial treatment have been initiated, although success is not certain.

**Limitations**

Antimicrobial consumption outside hospital was extracted from the nationwide portal FMK (common medication chart), a database of the Danish Health Authority that encompasses information of electronic prescriptions and purchase of all Danish citizens.

**Declaration of competing interest**

The authors have no competing interest to declare.

**Funding**

The project received no external financial support.

**Ethics**

The three infective endocarditis patients gave written permission (to KP) to publish their case stories.

**Author contributions**

NNL conceived the case series and performed bioinformatics analysis of whole-genome sequences. KP extracted and formulated clinical data. NNL wrote the first draft of the paper, which was revised critically for important intellectual content by ED, KP, and LPSR. All authors approved the final version of the manuscript. Marlene Lyngborg Tofterup, Odense University Hospital, is thanked for revision of transesophageal echocardiography of case 2.

## Data availability

The Whole-Genome Shotgun project PRJNA1009783 has been deposited at DDBJ/ENA/GenBank under accession numbers JAVIFB000000000-JAVIFD000000000 (cases 1-3; the isolate from case 3 is from the first bacteremia episode).

## References

- [1] Berisha B, Ragnarsson S, Olaison L, Rasmussen M. Microbiological etiology in prosthetic valve endocarditis: a nationwide registry study. *J Intern Med* 2022;**292**:428–37. doi:[10.1111/joim.13491](https://doi.org/10.1111/joim.13491).
- [2] Karlsson J, Kamenska N, Matuschek E, Brüggemann H, Söderquist B. *Cutibacterium avidum*: a potent and underestimated pathogen in prosthetic hip joint Infections. *Microorganisms* 2024;**12**(3):432–12. doi:[10.3390/microorganisms12030432](https://doi.org/10.3390/microorganisms12030432).
- [3] Corvec S. Clinical and biological features of *Cutibacterium* (formerly *Propionibacterium*) *avidum*, an underrecognized microorganism. *Clin Microbiol Rev* 2018;**31**:e00064–e00017. doi:[10.1128/CMR.00064-17](https://doi.org/10.1128/CMR.00064-17).
- [4] Østergaard L, Voldstedlund M, Bruun NE, Bundgaard H, Iversen K, Køber N, et al. Prevalence and mortality of infective endocarditis in community-acquired and healthcare-associated *Staphylococcus aureus* bacteremia: a Danish nationwide registry-based cohort study. *Open Forum Infect Dis* 2022;**9**:ofac647. doi:[10.1093/ofid/ofac647](https://doi.org/10.1093/ofid/ofac647).
- [5] Bossard DA, Ledergerber B, Zingg PO, Gerber C, Zinkernagel AS, Zbinden R, et al. Optimal length of cultivation time for isolation of *Propionibacterium acnes* in suspected bone and joint infections is more than 7 days. *J Clin Microbiol* 2016;**54**:3043–9. doi:[10.1128/JCM.01435-16](https://doi.org/10.1128/JCM.01435-16).
- [6] Ellsworth HS, Zhang L, Keener JD, Burnham CD, Aleem AW. Ten-day culture incubation time can accurately detect bacterial infection in periprosthetic infection in shoulder arthroplasty. *JSES Int* 2020;**4**:372–6. doi:[10.1016/j.jseint.2019.12.006](https://doi.org/10.1016/j.jseint.2019.12.006).
- [7] Fihman V, Faury H, Moussafeur A, Huguet R, Galy A, Gallien S, et al. Blood cultures for the diagnosis of infective endocarditis: what is the benefit of prolonged incubation? *J Clin Med* 2021;**10**:5824. doi:[10.3390/jcm10245824](https://doi.org/10.3390/jcm10245824).
- [8] Heinen FJ, Arregle F, van den Brink FS, Ajmone Marsan N, Bernts L, Houthuizen P, et al. Clinical Characteristics and Outcomes of Patients with *Cutibacterium acnes* Endocarditis. *JAMA Netw Open* 2023;**6**:e2323112. doi:[10.1001/jamanetworkopen.2023.23112](https://doi.org/10.1001/jamanetworkopen.2023.23112).
- [9] Andersen C, Gabrielaite M, Nørskov-Lauritsen N. Induction of Broad  $\beta$ -lactam Resistance in *Achromobacter ruhlandii* by Exposure to ticarcillin Is Primarily Linked to Substitutions in murein Peptide Ligase Mpl. *Microorganisms* 2022;**10**:420. doi:[10.3390/microorganisms10020420](https://doi.org/10.3390/microorganisms10020420).
- [10] Nedergaard S, Kobel CM, Nielsen MB, Møller RT, Jensen AB, Nørskov-Lauritsen N. Whole genome sequencing of *Aggregatibacter actinomycetemcomitans* cultured from blood stream infections reveals three major phylogenetic groups including a novel lineage expressing serotype a membrane O polysaccharide. *Pathogens* 2019;**8**:256. doi:[10.3390/pathogens8040256](https://doi.org/10.3390/pathogens8040256).