



University of Southern Denmark

**Discriminative and convergent validity of strain elastography for detecting tendinopathy within the supraspinatus tendon
a cross-sectional study**

Brage, Karen; Hjarbaek, John; Boyle, Eleanor; Ingwersen, Kim Gordon; Kjaer, Per; Juul-Kristensen, Birgit

Published in:
JSES International

DOI:
10.1016/j.jseint.2019.12.008

Publication date:
2020

Document version:
Final published version

Document license:
CC BY-NC-ND

Citation for pulished version (APA):

Brage, K., Hjarbaek, J., Boyle, E., Ingwersen, K. G., Kjaer, P., & Juul-Kristensen, B. (2020). Discriminative and convergent validity of strain elastography for detecting tendinopathy within the supraspinatus tendon: a cross-sectional study. *JSES International*, 4(2), 310-317. <https://doi.org/10.1016/j.jseint.2019.12.008>

Go to publication entry in University of Southern Denmark's Research Portal

Terms of use

This work is brought to you by the University of Southern Denmark.
Unless otherwise specified it has been shared according to the terms for self-archiving.
If no other license is stated, these terms apply:

- You may download this work for personal use only.
- You may not further distribute the material or use it for any profit-making activity or commercial gain
- You may freely distribute the URL identifying this open access version

If you believe that this document breaches copyright please contact us providing details and we will investigate your claim.
Please direct all enquiries to puresupport@bib.sdu.dk



Discriminative and convergent validity of strain elastography for detecting tendinopathy within the supraspinatus tendon: a cross-sectional study

Karen Brage, MSc ^{a,b,*}, John Hjarbaek, MD ^c, Eleanor Boyle, PhD ^a,
Kim Gordon Ingwersen, PhD ^d, Per Kjaer, PhD ^{a,b}, Birgit Juul-Kristensen, PhD ^a

^a Department of Sports Science and Clinical Biomechanics, University of Southern Denmark, Odense, Denmark

^b Health Sciences Research Centre, UCL University College, Odense, Denmark

^c Department of Radiology, Odense University Hospital, Odense, Denmark

^d Research Unit in Physiotherapy and Occupational Therapy, Hospital Lillebaelt, Vejle, Denmark

ARTICLE INFO

Keywords:

Strain elastography
supraspinatus tendon
rotator cuff
ultrasound
tendon quality
validity
tendinopathy
tendinosis

Level of evidence: Level IV; Case-Control
Design; Diagnostic Study

Background: We aimed to explore the discriminative validity of ultrasound strain elastography (SEL) between patients with painful supraspinatus tendinopathy and healthy control shoulders, as well as the associations between SEL and magnetic resonance imaging (MRI), conventional ultrasound (tendon thickness), and the Disabilities of the Arm, Shoulder and Hand questionnaire (DASH).

Methods: Thirty patients with shoulder pain and MRI-verified supraspinatus tendinopathy and 30 healthy control shoulders (no pain) were examined using SEL, MRI, and conventional ultrasound of the supraspinatus tendon. SEL variables included raw data, ratios between the deltoid muscle and supraspinatus tendon (deltoid ratio), color rating, and presence of red/yellow lesions (middle, worst part, and total tendon).

Results: Statistically significant increases in odds ratios for being symptomatic (increased softening) were seen for all raw data variables, corresponding to 3.978 (95% confidence interval [CI], 1.414–11.197) for middle, 4.602 (95% CI, 1.536–13.788) for worst, and 4.865 (95% CI, 1.406–16.836) for total tendon, and 1.260 (95% CI, 1.027–1.545) for the deltoid ratio (worst), adjusted for sex and body mass index (BMI). Tendon thickness was not associated with SEL; however, significantly positive associations were found between raw data variables and MRI ($\beta \geq 0.58$, $P < .01$), and positive associations were found between raw data variables and the DASH score ($\beta = 0.01$, $P \leq .04$), adjusted for sex and BMI.

Conclusions: Raw data variables and the deltoid ratio (worst) discriminated between patients with painful supraspinatus tendinopathy and healthy control shoulders when adjusted for sex and BMI. Associations were statistically significant for raw data variables and MRI or DASH score when adjusted for sex and BMI. Further studies are needed to understand SEL and the role of sex and BMI, including the responsiveness of SEL.

© 2020 The Authors. Published by Elsevier Inc. on behalf of American Shoulder and Elbow Surgeons. This is an open access article under the CC BY-NC-ND license (<http://creativecommons.org/licenses/by-nc-nd/4.0/>).

The lifetime prevalence of shoulder pain in the general population is up to 67%,¹⁹ and the most common shoulder diagnosis is subacromial pain syndrome,³² which often substantially decreases a patient's quality of life.²⁰ "Subacromial pain syndrome" is a generic term involving pain in the subacromial area and covers

supraspinatus tendinopathy, subacromial bursitis, and biceps tendon pathology.⁶ The last stage in the process of developing chronic tendinopathy involves large vascular alterations and collagen breakdown²⁹ that may change the mechanical properties of the tendon, resulting in tissue softening compared with healthy tissue. Imaging techniques such as radiography, conventional ultrasound, and magnetic resonance imaging (MRI) are common paraclinical examination methods to complement orthopedic tests and history taking when diagnosing supraspinatus tendinopathy.²⁵ However, abnormal imaging findings are reported in up to 62% of asymptomatic individuals when traditional imaging methods are used,³⁰ highlighting the need for modalities with better discriminating capabilities.

The study protocol was approved by the Ethics Committee of the Region of South Denmark (S-20160115), reported to the Danish Data Protection Agency (2014-41-3266), and registered at ClinicalTrials.gov (NCT03425344).

* Corresponding author: Karen Brage, MSc, Department of Sports Science and Clinical Biomechanics, University of Southern Denmark, Campusvej 55, 5230 Odense, Denmark.

E-mail address: kabr2@ucl.dk (K. Brage).

<https://doi.org/10.1016/j.jseint.2019.12.008>

2666-6383/© 2020 The Authors. Published by Elsevier Inc. on behalf of American Shoulder and Elbow Surgeons. This is an open access article under the CC BY-NC-ND license (<http://creativecommons.org/licenses/by-nc-nd/4.0/>).

A new ultrasound imaging technique in the musculoskeletal field called “strain elastography” (SEL) has recently gained attention, as the method indicates potential for diagnosis, prediction (pain, treatment outcome, return to previous activities), and monitoring of tendon healing, as seen in a recent review.²⁶ Generally, SEL is based on a technique involving repeated manual compressions of the tissue with a transducer to obtain an axial strain, resulting in variations in deformation between soft and stiff tissue. To achieve the raw SEL result, the correlation between the echo signal before and after compression is calculated. The elasticity of the tissue is expressed by the Young modulus (Y) by the following formula, in which stress is the externally applied force and strain is the internal response in the form of tissue deformation: $Y = \text{Stress}/\text{Strain}$. Because there are no direct measurements of stress using SEL, it is hypothesized that presenting a ratio between the area of interest and a reference area (provided both areas are subjected to the same amount of manual pressure, ie, the same tissue depth) will produce the most reliable results.^{7,8}

Unlike conventional ultrasound and MRI methods, SEL is able to measure mechanical properties, which may add valuable information to standard shoulder examinations, as well as provide the surgeon with information about tendon quality. The reliability of SEL in the supraspinatus tendon has recently been shown to be acceptable.^{2,17,22}

The discriminative validity of SEL in the supraspinatus tendon, however, has only been investigated in 2 studies, to our knowledge, both reporting softening of the symptomatic tendons.^{17,31} One of the studies included participants with small supraspinatus tendon tears,³¹ whereas the other included participants with supraspinatus tendinopathy.¹⁷ However, no studies have investigated the discriminative validity of SEL comparing both its quantitative and clinically applicable (qualitative) variables in patients with supraspinatus tendinopathy vs. healthy control shoulders.

For convergent validity, the correlation between SEL and MRI has been reported in patients with supraspinatus tendinopathy,^{18,28,33} using different methods (strain ratios or color scales), but the methods have, to our knowledge, not yet been compared with each other. The correlation between SEL and conventional ultrasound (tendon thickening and echo structure) has only been evaluated using a qualitative color scale.²⁸ Therefore, there is a need to further explore associations between SEL and both MRI and conventional ultrasound. Furthermore, because there are contrasting results on correlations between SEL and self-reported function,^{17,31} there is a need for further investigation.

Therefore, the objective of this study was first to test the discriminative validity of SEL between patients with supraspinatus tendinopathy and healthy control shoulders, hypothesizing that patients would have softer tendons than controls. The second objective was to investigate the associations between SEL and MRI, conventional ultrasound (tendon thickness), and the Disabilities of the Arm, Shoulder and Hand (DASH) score, with the hypothesis that tendons would be softer (determined by SEL) with increased severity of tendinopathy (verified by MRI), tendon thickness, and disability.

Materials and methods

This was a cross-sectional study, using the guidelines outlined in Strengthening the Reporting of Observational Studies in Epidemiology (STROBE) statement,³⁴ as well as Consensus based Standards for the Selection of Health Measurement Instruments (COSMIN), hypothesis testing for construct validity.²¹ Patients and controls were recruited from March to December 2018. Shoulder patients were recruited from the Radiology Department at Odense University Hospital, Denmark, if they received a diagnosis of tendinopathy

via MRI, and from the Orthopedic Department at Hospital Lillebaelt, Vejle, Denmark, if they had clinical signs of tendinopathy. Controls with no shoulder symptoms were recruited via social media and the local press. Patients recruited from Vejle Hospital, as well as healthy control shoulders, were referred for MRI after inclusion. Patients were excluded if no MRI-verified tendinopathy was found.

Except for MRI measurements carried out at the hospital, all procedures were performed at the University of Southern Denmark. After inclusion, patients and healthy control shoulders underwent clinical tests and conventional ultrasound, performed by a shoulder clinician (G.K.I.) with more than 11 years of experience in the shoulder area, who was blinded to the MRI and SEL findings. MRI ratings were performed by a radiologist (J.H.) with more than 20 years of experience in assessing musculoskeletal MRI findings. Initially, when participants entered the study, the radiologist had access to each patient's history while determining from the MRI images whether the patient met the study's inclusion and exclusion criteria. Approximately 6 months after inclusion, MRI ratings were performed again by the same radiologist (mixed with 20 MRI images of both healthy and unhealthy persons from other studies) to secure blinding from their patient history. During the first as well as second MRI ratings, the radiologist was blinded to the conventional ultrasound and SEL findings.

All participants completed questionnaires on shoulder pain, function, and quality of life. Afterward, SEL and additional testing procedures were performed, lasting approximately 1 hour. All SEL images were performed by the same clinician (K.B.), a radiographer with 3 years of experience in musculoskeletal SEL. SEL images were stored for at least 14 days after image capturing until image assessment, to ensure blinding of K.B., as previously described.² All participants were given oral and written information about the study, and before participation, they provided written informed consent.

Participants

Inclusion and exclusion criteria

The inclusion criteria for both patients and healthy control shoulders were age between 40 and 60 years (to exclude severe age-related tendon degeneration) and body mass index (BMI) lower than 30 (to optimize image quality). Patients had to have MRI-verified supraspinatus tendinopathy of grade 1 or higher,²⁷ shoulder pain for at least 3 months, and at least 3 positive findings among the following 5 clinical tests: full-can test,¹² Jobe test,¹¹ resisted external rotation test,¹³ Hawkins-Kennedy test,⁹ and Neer test.²³ The inclusion criteria for healthy control shoulders were no shoulder symptoms during the past year and negative findings on all 5 clinical tests.

The general exclusion criteria for both groups were previous shoulder fractures, surgery or luxation, known neuromuscular disease, rheumatoid arthritis, fibromyalgia, spondyloarthropathy, cancer, psychiatric disorders, pregnancy (because of potentially altered tissue elasticity), and inability to read and understand Danish. Specific radiologic exclusion criteria based on routine MRI ratings for both groups were supraspinatus tears larger than one-third of the vertical height of the tendon, calcifications larger than 2 mm owing to acoustic shadowing, ruptures of the rotator cuff and biceps tendon, and labral lesions.

Strain elastography

Apparatus

A Logiq S7 system (GE Healthcare, Milwaukee, WI, USA) fitted with a 15-MHz linear probe was used for all SEL measurements, with settings following the manufacturer's recommendations.

Patient placement

SEL scanning and imaging of the supraspinatus tendon were performed with the patient sitting erect and the selected upper limb fixed in a standardized position (Fig. 1).

Image capturing

SEL imaging procedures were based on the method described previously.² In brief, 20-second image-capturing sequences were performed longitudinally on the supraspinatus tendon, maintaining the same probe position, as well as the arm and body position of the participant. Conventional ultrasound was used to locate the most affected part of the tendon in terms of thickening, hypoechoic areas, and neovascularization. The image width was set to cover approximately 75% of the screen, with an image window depth of a minimum of 3 times the tendon size.⁵ Recommended tissue compression of about 2–5 mm was used.⁸ The in-built quality bar was used to assess the recommended compression mode. Following the manufacturer's recommendation, only cine sequences with 5 green points on the quality bar were used. The tendon was divided into 3 sections as previously described,² and SEL was reported for the middle part of the tendon (on which the sample size was calculated), the worst part of the tendon, and the total tendon (mean of the medial, middle, and lateral parts).

Image measurements

Tendon characteristics were assessed by quantitative and qualitative SEL variables. Quantitatively, regions of interest on the SEL images were drawn over each of the target areas, and the exact raw value was calculated using a scale from 0–6, with 0 being softest and 6 being stiffest.²

For calculation of the deltoid ratio (tendon to reference), a reference area of a 5-mm circle of tissue in a soft (red) part of the deltoid was drawn. The scale of the deltoid ratio ranged from 0–60, with 0 being softest and 60 being stiffest.^{2,17} In the interest of avoiding transient temporal fluctuations and minimizing intra-observer variation, we based all quantitative measurements on a mean of 3 cine loops.⁴

Qualitatively, tendon characteristics were classified based on color ratings from the regions of interest drawn for raw-value SEL images, using a scale from 1–4, according to the following: type 1, greater than 50% color other than blue (softest tissue); type 2, 26%–50% color other than blue; type 3, 10%–25% color other than blue; and type 4, less than 10% color other than blue (stiffest tissue).² For the regression analysis, data were dichotomized into at least 26% color other than blue (soft tendon, types 3 and 4) and less than 26% color other than blue (stiff tendon, types 1 and 2).²

Counting of red/yellow lesions was performed^{2,28} and dichotomized for the regression analysis into the presence or absence of red/yellow lesions (Fig. 2). Three cycles of compression and decompression were performed, and the first high-quality image between 5 and 15 seconds in the best cycle was used for all qualitative classifications.^{4,15}

Magnetic resonance imaging

MRI capturing was performed according to the hospital's standardized noncontrast shoulder MRI protocol and rated using a previously established reliable protocol.²⁷ The MRI scan was rated using a 4-level scale (0–3) as follows: grade 0 (normal), a tendon with complete homogeneous low intensity on all pulse sequences or minor intratendinous signal hyperintensity consistent with the magic angle; grade 1 (mild tendinopathy), a mild focal increase in tendon signal on proton density and fat-suppressed T2 sequencing not equal to that of fluid; grade 2 (moderate tendinopathy), a moderate focal increase in tendon signal on proton density and fat-

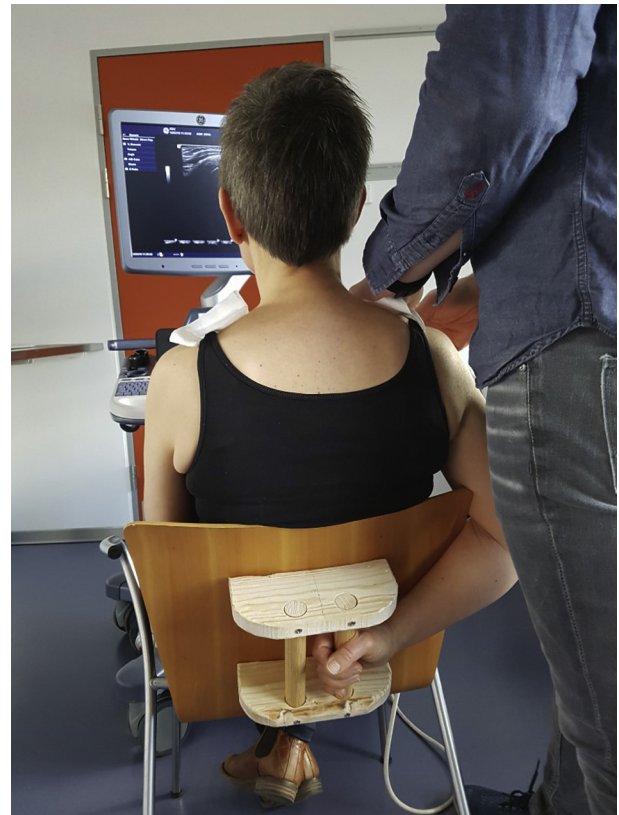


Figure 1 Strain elastography and conventional ultrasound (tendon thickness) were performed while the participant was sitting in a custom-made chair with the selected upper limb fixed in a standardized position.

suppressed T2 sequencing not equal to that of fluid; and grade 3 (marked tendinopathy), a marked generalized increase in tendon signal without frank fluid signal intensity.²⁷ For the second aim, MRI ratings were dichotomized into absence (grade 0) or presence (grades 1–3) of tendinopathy.

The duration between MRI capturing including analyses and the primary examinations (clinical tests, conventional ultrasound, SEL, and questionnaires) was 8 days on average for patients vs. 60 days for healthy control shoulders. To ensure stability of the inclusion criteria, healthy control shoulders were excluded if they had experienced any changed shoulder condition during this period.

Ultrasound

Tendon thickness was measured using the Logiq S7 system, with a 6.0- to 15.0-MHz dedicated probe. Image capturing was

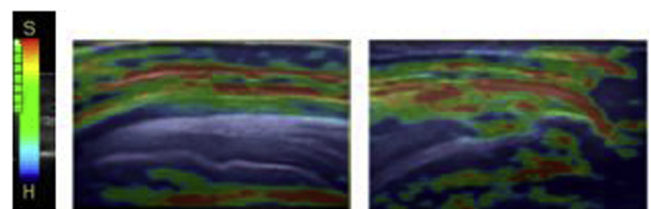


Figure 2 The reference bar (left) indicates that soft tissue (s) is shown in red whereas stiff or hard tissue (h) is shown in blue. Imaging showed an asymptomatic and homogeneously blue (and stiff) supraspinatus tendon (middle) and a symptomatic supraspinatus tendon (right), with green, yellow, and red areas indicating signs of softening.

performed using a standardized and reliable protocol¹⁰ at 12.0 MHz and 54% gain, using the manufacturer's recommendations for musculoskeletal imaging of the shoulder.

Questionnaires and demographic data

Participants filled out the following questionnaires: DASH, investigating disability of the upper extremities¹⁴; visual analog scale (pain score of 0–100, with 100 being the most painful),¹ measured at rest, with activity, and with sleep, as well as the maximum; EQ-5D-3L, measuring 5 dimensions of health-related quality of life; and EQ-VAS, measuring general health-related quality of life (0–100, with 100 being best imaginable health status).²⁴ Demographic characteristics included information on age, sex, BMI, duration and origins of symptoms, hand dominance, workload and ability, and concomitant corticoid steroid injection within the past 6 weeks.

Statistics

A histogram with a normal distribution curve was used to verify continuous data for normality, which was confirmed for the raw-value SEL data, deltoid ratio, and tendon thickness (from conventional ultrasound). Descriptive statistics were used for demographic and SEL characteristics of the patients and healthy control shoulders, including mean \pm standard deviation for normally distributed continuous data (raw-value variables), median (interquartile range) for non-normally distributed data (color ratings), and number and percentage for ordinal and nominal data (eg, number of red/yellow lesions).

Logistic regression analysis was used to test whether SEL variables could identify patients with supraspinatus tendinopathy (as defined by MRI and clinical signs). To ease the interpretation of the logistic regression model, the SEL scales were reversed, meaning that an odds ratio greater than 1 should be interpreted as increased tissue softening that characterizes a patient with supraspinatus tendinopathy.

Linear regression analyses were used to test for associations between quantitative variables of SEL (raw-value variables and deltoid ratio) and MRI, tendon thickness, and the DASH score. The scale was reversed so that a positive β coefficient would be interpreted as increased tissue softening.

For associations between the qualitative SEL variables (color ratings and presence of red/yellow lesions) and MRI, tendon thickness, and the DASH score, logistic regression analyses were conducted and interpreted such that an odds ratio greater than 1 indicated an increase in tissue softening. Previous studies have shown that age, sex, and BMI may have an effect on tendon stiffness; this is why these factors were included in the regression models.^{3,31} For all regression models, the unadjusted model was first fitted. This was followed by adding each covariate (age, sex, and BMI) separately into the model to determine whether the addition of the respective covariate changed the β coefficient of the independent variable by more than 10%. Finally, the adjusted model was fitted with the relevant covariates (sex and BMI).

Sample size was based on raw elastography variables with mean values of 4.16 (standard deviation, 0.63) for patients and 4.58 (standard deviation, 0.50) for healthy control shoulders.² For a 2-sided pooled sample, significance level of .05, and power of 80%, a sample size of a minimum of 30 persons per group was required to achieve a statistically significant group difference. Statistical significance was defined as $P \leq .05$, and statistical analyses were carried out using SPSS software (version 25.0; IBM, Armonk, NY, USA).

Results

Patients and healthy control shoulders were comparable regarding age, sex, BMI, dominant arm scanned, and tendon thickness (Table I). Patients had more pain, disability, and tendon changes on MRI, in addition to a more reduced quality of life and workability, than healthy control shoulders. Three healthy control shoulders did not undergo MRI scanning owing to unknown circumstances (Table I).

The difference in SEL between patients and healthy control shoulders ranged between -0.29 and -0.20 for raw-value variables (0–6 scale) and between -1.33 and -1.12 for the deltoid ratio (0–60 ratio scale), indicating that patients may have had a softer supraspinatus tendon than healthy control shoulders. No between-group differences were found in terms of color rating or number of red/yellow lesions (Table II).

For all raw-value variables and the deltoid ratio (worst), the odds of being a patient with supraspinatus tendinopathy (tendon softening) were statistically significantly increased (3.978, 4.602, 4.865, and 1.260) when taking into account sex and BMI (Table III). No significant odds ratios were noted for color rating and the presence of red/yellow lesions in relation to being a patient.

Table I

Demographic data for patients with supraspinatus tendinopathy and healthy control shoulders (N = 60)

Variable	Patients (n = 30)	Controls (n = 30)
Age, yr	51 (10.3)	47 (5.0)
Women, n (%)	17 (56.7)	21 (70.0)
BMI	26.76 (5.09)	24.39 (4.73)
Duration of symptoms, mo	9.5 (17.25)	—
Dominant arm scanned, n (%)	18 (60.0)	14 (46.7)
Workload, present occupation (0–10 [in which 10 indicates very physically heavy])	5 (5)*	3 (4)†
Work ability (0–10 [in which 10 indicates very high])	8 (4)	10 (1)
Corticosteroid injection (within past 6 wk), n (%)	4 (13.3)	0 (0.0)
Symptom history, n (%)		
Accident or acute incidence	5 (16.7)	—
Slow consistent development (overload)	13 (43.3)	—
Unknown	12 (40)	—
Pain intensity: VAS score		
Rest (0–100)	30.0 (36.8)	0.0 (0.0)
Activity (0–100)	58.0 (20.5)	0.0 (0.0)
Sleep (0–100)	50.5 (32.5)	0.0 (0.0)
Maximum (0–100)	78.5 (14.8)	0.0 (0.0)
DASH score	31.5 (16.0)	0.0 (2.0)
EQ-5D-3L, n (%)		
Mobility problems	2 (6.7)	0 (0.0)
Self-care problems	10 (33.3)	0 (0.0)
Usual activities problems	24 (80.0)	0 (0.0)
Pain/discomfort problems	30 (100.0)	0 (0.0)
Anxiety problems	4 (13.3)	0 (0.0)
EQ-VAS (0–100)	60 (72.0)	95 (30.5)
MRI (grade), n (%)‡		
0: normal	0 (0.0)	12 (40.0)
1: mild tendinopathy	11 (36.7)	11 (36.7)
2: moderate tendinopathy	16 (53.3)	4 (13.3)
3: severe tendinopathy	2 (6.7)	0 (0.0)
Tendon thickness (UL), mean \pm SD, mm	7.76 \pm 1.11	7.48 \pm 1.02

BMI, body mass index; VAS, visual analog scale (0–100); DASH, Disabilities of the Arm, Shoulder and Hand questionnaire (0–100); EQ-5D-3L, quality of life by health dimension; EQ-VAS, quality of life (0–100); MRI, magnetic resonance imaging; SD, standard deviation; UL, conventional ultrasound.

Data are presented as median (interquartile range) unless otherwise indicated.

* The group comprised 27 patients (as 3 patients were not employed).

† The group comprised 29 patients (as 1 control was not employed).

‡ Three controls did not undergo magnetic resonance imaging scans.

Table II
Descriptive values of strain elastography variables for raw values, deltoid ratio, color rating, and number of red/yellow lesions for patients with supraspinatus tendinopathy and healthy control shoulders (N = 60)

Variable	Patients (n = 30)	Controls (n = 30)	Difference
Raw values			
Middle tendon part	3.42 ± 0.81	3.68 ± 0.73	-0.26
Worst tendon part	3.10 ± 0.68	3.39 ± 0.66	-0.29
Total tendon	3.55 ± 0.66	3.75 ± 0.61	-0.21
Deltoid ratio (tendon-deltoid muscle)			
Middle tendon part	11.30 ± 4.07	12.59 ± 4.11	-1.56
Worst tendon part	10.25 ± 3.32	11.58 ± 3.41	-1.33
Total tendon	11.69 ± 3.64	12.81 ± 3.50	-1.12
Color rating, n (%)			
Middle tendon part			
<10% not blue (hardest tissue)	10 (33.3)	13 (43.3)	-10
10%-25% not blue	11 (36.7)	8 (26.7)	-3
26%-50% not blue than blue	4 (13.3)	6 (20)	2
>50% not blue (softest tissue)	5 (16.7)	3 (10)	-2
Worst tendon part			
<10% not blue (hardest tissue)	5 (16.7)	11 (36.7)	6
10%-25% not blue	11 (36.7)	7 (23.3)	-4
26%-50% not blue	4 (13.3)	9 (30)	5
>50% not blue (softest tissue)	10 (33.3)	3 (10)	-7
Total tendon			
<10% not blue (hardest tissue)	5 (16.7)	10 (33.3)	5
10%-25% not blue	13 (43.3)	5 (16.7)	-8
26%-50% not blue	6 (20)	9 (30)	3
>50% not blue (softest tissue)	6 (20)	6 (20)	0
No. of red/yellow lesions (%)			
Middle tendon third			
0	22 (73.3)	21 (70)	-1
1	4 (13.3)	6 (20)	2
2	2 (6.7)	2 (6.7)	0
≥3	2 (6.7)	1 (3.3)	-1
Worst tendon part			
0	9 (30)	14 (46.7)	5
1	12 (40)	8 (26.7)	-4
2	6 (20)	5 (16.7)	-1
≥3	3 (10)	3 (10)	0
Total tendon			
0	10 (33.3)	14 (46.7)	4
1	10 (33.3)	6 (20)	-4
2	6 (20)	5 (16.7)	-1
≥3	4 (13.3)	5 (16.7)	1

Data are presented as mean ± standard deviation for raw values, median (interquartile range) for deltoid ratio, and count (percentage) for color rating and number of red/yellow lesions. Raw values comprise raw elastography data, and the deltoid ratio is defined as the ratio between the supraspinatus tendon and a soft area in the deltoid muscle.

Statistically significant positive associations were found between raw-value variables and MRI ($\beta \geq 0.58-0.70$, $P < .01$) (adjusted model), as well as between raw-value variables and the DASH score ($\beta = 0.01$, $P \leq .04$) (adjusted model). This finding means that participants with MRI-verified tendinopathy (grades 1-3) had a softer tendon than participants without MRI-verified tendinopathy (grade 0). Furthermore, for every unit increase in the DASH score (worse ratings of disability), increased softening was evidenced in the raw-value variables. This study found statistically significant associations neither for the deltoid ratio (Table IV) nor for color ratings and the presence of red/yellow lesions (Table V) in relation to MRI, tendon thickness, and the DASH score.

Discussion

Statistically significant odds ratios for being symptomatic with clinical and MRI-verified tendinopathy were found with soft tendons regarding quantitative SEL variables (raw-value variables and deltoid ratio [worst]) when adjusting for sex and BMI. Both the deltoid ratios for the middle and total showed the same tendency; however, they were not significant. In contrast, these results were not confirmed for the clinically qualitative color ratings and presence of red/yellow lesions.

Furthermore, statistically significant associations were found between the quantitative raw-value variables and MRI, in addition to the DASH score, meaning that for a participant with MRI-verified tendinopathy and an increased DASH score (worsening of disability), the score on the raw-value variables (softening) was increased when adjusting for sex and BMI. No associations were found for the quantitative deltoid ratio or qualitative variables (color ratings and presence of red/yellow lesions) and MRI or the DASH score. No associations were found between quantitative or qualitative SEL variables and tendon thickness.

Discriminative validity

This study found supraspinatus tendon softening in symptomatic participants that can be explained histologically by loss of collagen structure, increased water content, fatty infiltration, and capillary proliferation.¹⁶ This new information regarding tendon softness may have clinical implications in preclinical stages and early diagnosis. Unfortunately, no previous studies have reported raw-value variables in patients with supraspinatus tendinopathy, so comparisons are not possible.

The current results of the deltoid ratio (worst) are in line with the findings of a study also using the deltoid muscle as reference

Table III
Discriminative validity (associations) with OR for patients having supraspinatus tendinopathy for strain elastography variables in unadjusted and adjusted models (for sex and BMI) for patients with supraspinatus tendinopathy and healthy control shoulders (N = 60)

Variable	OR (95% CI)	
	Unadjusted model	Adjusted model
Continuous scale		
Raw values		
Middle tendon part	1.578 (0.795–3.131)	3.978 (1.414–11.197)*
Worst tendon part	1.931 (0.856–13.788)	4.602 (1.536–13.788)*
Total tendon	1.716 (0.743–3.966)	4.865 (1.406–16.836)*
Deltoid ratio		
Middle tendon part	1.086 (0.948–1.244)	1.188 (1.000–1.411)
Worst tendon part	1.134 (0.960–1.340)	1.260 (1.027–1.545)*
Total tendon	1.097 (0.943–1.277)	1.203 (0.995–1.454)
Dichotomous scale		
Color rating (≥26% color other than blue [soft] vs. <26% color other than blue [hard])		
Middle tendon part	1.179 (0.383–3.629)	1.675 (0.485–5.783)
Worst tendon part	0.875 (0.318–2.410)	1.521 (0.470–4.922)
Total tendon	1.00 (0.356–2.809)	1.408 (0.455–4.358)
No. of red/yellow lesions (having lesions vs. not having lesions)		
Middle tendon part	0.848 (0.276–2.612)	1.100 (0.333–3.635)
Worst tendon part	2.042 (0.707–5.895)	3.484 (0.970–12.517)
Total tendon	2.698 (0.804–9.060)	2.698 (0.804–9.060)

OR, odds ratio; BMI, body mass index; CI, confidence interval.
Raw values comprise raw elastography data, and the deltoid ratio is defined as the ratio between the supraspinatus tendon and a soft area in the deltoid muscle.
* Significant difference.

tissue in patients with supraspinatus tendinopathy.¹⁷ The study showed that symptomatic tendons with tendinopathy were significantly softer than the asymptomatic contralateral tendon when focusing on the worst part of the tendon (strain index, 0.71 ± 0.25 vs. 0.24 ± 0.10; n = 25). Of note, the SEL ratio was calculated

oppositely (ie, the denominator being the tendon as opposed to the denominator being the reference tissue in our study), thereby reversing the result,¹⁷ in contrast to our study.

A study using another reference tissue (bone) in patients with symptomatic small unilateral supraspinatus tears also supports the current results, as symptomatic supraspinatus tendons were significantly softer than asymptomatic tendons (no MRI) (strain index, 0.75 ± 0.08 vs. 1.01 ± 0.07; n = 50).³¹ However, the different patient group (with more pronounced soft areas in supraspinatus tears) may explain why only one of the current ratios (deltoid ratio for the worst part) had significantly increased odds of classifying participants as being symptomatic.

Unlike our study, the study by Kocyigit et al¹⁷ found a statistically significant difference between supraspinatus impingement and healthy contralateral shoulders with color ratings. However, this difference could be a result of different inclusion criteria (broader criteria for impingement than for the current tendinopathy) and age (larger age range of 18–65 years than the current range of 40–60 years), potentially causing a larger variation, as well as more elderly patients with soft tissues and young persons with stiff contralateral healthy tendons.

Convergent validity

This study found significantly positive associations, when adjusting for sex and BMI, between the quantitative raw-value variables and MRI but not between the deltoid ratio and MRI. This finding is in contrast to the results of 2 previous studies in patients with supraspinatus tendinopathy showing significantly positive associations between SEL ratios and MRI.^{18,33} Different reference tissues, such as fat and a gel pad,¹⁸ and a healthy area in the supraspinatus tendon,³³ potentially with larger tissue contrasts, may explain the different results in these ratios.

Our study found no associations for the qualitative variables (color ratings and presence of red/yellow lesions) and MRI, in contrast to a previous study in which a significantly positive correlation (r = 0.83) was found between the presence of red/yellow

Table IV
Convergent validity (associations) with OR for patients having softening of tendon with linear regression between strain elastography variables (raw values and deltoid ratio) for having softening of tendon and DASH score, MRI (binary), and tendon thickness (conventional ultrasound) in unadjusted and adjusted models (for sex and BMI) for patients with supraspinatus tendinopathy and healthy control shoulders (N = 60)

Outcome variable (continuous scale)	Independent variable	Unadjusted model		Adjusted model	
		Regression coefficient, β (95% CI)	P value	Regression coefficient, β (95% CI)	P value
Raw values					
Middle tendon part	MRI	0.39 (−0.11 to 0.88)	.12	0.70 (0.29 to 1.11)	<.01*
Worst tendon part	MRI	0.40 (−0.05 to 0.84)	.08	0.66 (0.27 to 1.05)	<.01*
Total tendon	MRI	0.32 (−0.74 to 0.90)	.12	0.58 (0.24 to 0.93)	<.01*
Middle tendon part	Tendon thickness	0.02 (−0.03 to 0.04)	.12	0.01 (0.02 to 0.01)	.60
Worst tendon part	Tendon thickness	0.01 (−0.03 to 0.01)	.26	0.00 (0.02 to 0.02)	.86
Total tendon	Tendon thickness	−0.01 (−0.02 to 0.01)	.34	0.00 (−0.02 to 0.01)	.95
Middle tendon part	DASH	0.01 (−0.00 to 0.02)	.17	0.01 (0.00 to 0.02)	.02*
Worst tendon part	DASH	0.01 (−0.00 to 0.02)	.14	0.01 (0.00 to 0.02)	.02*
Total tendon	DASH	0.01 (−0.00 to 0.01)	.24	0.01 (0.00 to 0.02)	.04*
Deltoid ratio					
Middle tendon part	MRI	0.61 (−2.17 to 3.38)	.66	1.85 (−0.69 to 4.39)	.15
Worst tendon part	MRI	0.69 (−1.59 to 2.97)	.55	1.70 (−0.42 to 3.81)	.11
Total tendon	MRI	0.42 (−2.00 to 2.85)	.73	1.47 (−0.72 to 3.67)	.18
Middle tendon part	Tendon thickness	−0.05 (−0.15 to 0.05)	.36	−0.01 (−0.11 to 0.08)	.77
Worst tendon part	Tendon thickness	−0.03 (−0.11 to 0.06)	.52	−0.00 (−0.08 to 0.08)	.98
Total tendon	Tendon thickness	−0.02 (−0.11 to 0.07)	.62	0.01 (−0.08 to 0.09)	.94
Middle tendon part	DASH	0.04 (−0.02 to 0.10)	.21	0.05 (0.00 to 0.10)	.07
Worst tendon part	DASH	0.03 (−0.02 to 0.08)	.17	0.04 (−0.00 to 0.09)	.06
Total tendon	DASH	0.03 (−0.02 to 0.10)	.52	0.04 (−0.01 to 0.08)	.10

DASH, Disabilities of the Arm, Shoulder and Hand questionnaire (0–100); MRI, magnetic resonance imaging (dichotomous scale); BMI, body mass index; CI, confidence interval.
Raw values comprise raw elastography data, and the deltoid ratio is defined as the ratio between the supraspinatus tendon and a soft area in the deltoid muscle.
* Significant difference.

Table V
Convergent validity (associations) with OR for patients having soft tendon between strain elastography variables (color ratings and number of red/yellow lesions) and DASH score, MRI, and tendon thickness (conventional ultrasound) in unadjusted and adjusted models (potential confounders of sex and BMI) for patients with supraspinatus tendinopathy and healthy control shoulders (N = 60)

Outcome variable (dichotomous scale)	Independent variable	OR (95% CI)	
		Unadjusted model	Adjusted model
Color ratings ($\geq 26\%$ color other than blue [soft] vs. $< 26\%$ color other than blue [stiff])			
Middle tendon part	MRI	0.18 (0.02-1.50)	0.10 (0.01-1.00)
Worst tendon part	MRI	0.65 (0.18-2.37)	0.28 (0.06-1.30)
Total tendon	MRI	0.40 (0.10-1.68)	0.23 (0.05-1.12)
Middle tendon part	Tendon thickness	0.92 (0.86-1.00)	0.92 (0.85-1.00)
Worst tendon part	Tendon thickness	0.98 (0.93-1.02)	0.99 (0.95-1.06)
Total tendon	Tendon thickness	0.97 (0.92-1.02)	0.98 (0.93-1.04)
Middle tendon part	DASH	0.99 (0.96-1.02)	0.99 (0.96-1.03)
Worst tendon part	DASH	0.99 (0.96-1.02)	1.00 (0.97-1.03)
Total tendon	DASH	1.00 (0.97-1.03)	1.00 (0.98-1.03)
No. of red/yellow lesions (having lesions vs. not having lesions)			
Middle tendon part	MRI	0.80 (0.19-3.42)	0.57 (0.12-2.66)
Worst tendon part	MRI	0.72 (0.20-2.67)	0.43 (0.10-1.88)
Total tendon	MRI	0.80 (0.22-2.94)	0.51 (0.12-2.16)
Middle tendon part	Tendon thickness	0.96 (0.90-1.01)	0.96 (0.90-1.03)
Worst tendon part	Tendon thickness	0.99 (0.95-1.04)	1.01 (0.96-1.06)
Total tendon	Tendon thickness	1.00 (0.95-1.05)	1.01 (0.96-1.07)
Middle tendon part	DASH	1.00 (0.97-1.03)	1.00 (0.97-1.03)
Worst tendon part	DASH	0.98 (0.95-1.05)	1.03 (0.10-1.07)
Total tendon	DASH	0.98 (0.95-1.05)	1.03 (0.99-1.06)

DASH, Disabilities of the Arm, Shoulder and Hand questionnaire (0-100); MRI, magnetic resonance imaging (dichotomous scale); BMI, body mass index; OR, odds ratio; CI, confidence interval.

lesions and MRI (n = 118).²⁸ Some of the reasons for the difference may be the larger range in age (40-76 years vs. 40-60 years in our study), potentially with more signs of degenerative changes; different ultrasound equipment; and different MRI grading systems.

Neither the current quantitative nor qualitative SEL variables were found to be significantly associated with tendon thickness, in contrast to findings in the aforementioned study,²⁸ in which statistically significant correlations were found between conventional ultrasound measurements (echogenicity and tendon thickness) and the presence of red/yellow lesions. However, the grading system used did not include measurements of the exact tendon thickness,²⁸ which precludes comparison with our study.

The current statistically significant associations between SEL (raw-value variables) and self-reported function (DASH score) are in line with the previously mentioned study of patients with small supraspinatus tendon tears.³¹ In that study, correlations were found between SEL and self-reported as well as measured function (visual analog scale, Constant-Murley score, American Shoulder and Elbow Surgeons Shoulder Index, Simple Shoulder Test, and University of California at Los Angeles Shoulder Rating Scale).³¹

Furthermore, the current lack of significant associations between the qualitative variables of SEL (color ratings and presence of red/yellow lesions) and self-reported function (DASH score) are in line with a previous study of patients with tendinopathy,¹⁷ supporting a limited convergent validity of the qualitative variables (color rating and presence of red/yellow lesions) in relation to self-reported function (American Shoulder and Elbow Surgeons score; Quick Disabilities of the Arm, Shoulder and Hand questionnaire [QuickDASH] score; and Constant score).¹⁷

Limitations and strengths

Using SEL presents several challenges because manual compression is required and reliability of SEL may be poor. A previous study, however, showed good reliability in relation to repeated image analysis of the same SEL variables,² when the same operator captured the images and 2 raters analyzed the images, using the same standardized protocol for SEL as in our study. MRI scanning of the shoulder was performed using different types of MRI scanners,

but because the images were rated by the same radiologist using the same criteria, this is not likely to have biased the data.

The strict inclusion criterion of a relatively small age span (40-60 years) may have limited contrasts between patients and healthy controls. The current small age span may also be one reason age did not influence SEL. However, the age criterion was selected to be able to exclude severe age-related changes and only focus on tendinopathy-related changes. Therefore, in future studies, matching by sex, age, and BMI needs to be performed. Another limitation is that patients were not excluded if they had received a corticosteroid injection previously because this procedure may affect tissue elasticity.

Using the deltoid muscle as a reference may not be appropriate if SEL is measured over time because the deltoid muscle may potentially change stiffness after exercise treatment, causing the ratios to be affected. Unfortunately, the options for reference tissues during scanning of the supraspinatus tendon are limited. Previously, it was shown that using a gel pad was inappropriate as it has large minimal detectable change values.² Furthermore, reference tissues such as subcutaneous fat are limited in the shoulder area,² bone is not reliable because ultrasound cannot penetrate bone (generating artifacts), and a healthy (stiff) area in the supraspinatus tendon (eg, deltoid muscle) may change during interventions. Therefore, raw values may be the most appropriate variables with the disadvantage of being highly affected by manual compression.

The duration between MRI scanning, including analyses, and the primary examinations (clinical tests, conventional ultrasound, SEL, and questionnaires) for healthy control shoulders was a mean of 60 days, which may be regarded as a limitation. However, because healthy participants reporting changes in their shoulder were excluded from the study, this is not regarded as a limitation.

The strengths of the study are the use of a standardized and reliable method of capturing and analyzing images, including the region-of-interest placement and ratings. Additional strengths include (1) the use of 2 different, reliable quantitative methods (raw-value variables and deltoid ratio) and the fact that the validity of the raw-value variables had not previously been reported and (2) the use of 2 different, reliable qualitative methods (color ratings

and presence of red/yellow lesions), which have not previously had their discriminative validity assessed for differentiating between patients with supraspinatus tendinopathy and healthy control shoulders. The performance of blinded measurements on SEL, conventional ultrasound, and MRI is a further strength of this study.

Conclusion

The discriminative validity of ultrasound SEL between patients with painful supraspinatus tendinopathy and healthy control shoulders was confirmed for raw-value variables and the deltoid ratio for the worst part of the tendon. Moreover, significant associations with MRI and the DASH score were found for all raw-value variables when adjusting for sex and BMI. Therefore, SEL may be a useful diagnostic add-on tool for the diagnosis of supraspinatus tendinopathy. Further studies are needed to understand the SEL findings and the role of sex and BMI, in addition to the responsiveness of SEL.

Acknowledgments

The authors thank the staff at Odense and Svendborg University Hospitals for recruiting participants and performing MRI scanning and the staff at Hospital Lillebaelt, Vejle, for recruiting patients. They also thank Suzanne Capell for proofreading the manuscript.

Disclaimer

The following funding (noncommercial) bodies provided financial support: Region of South Denmark (Research Fund and PhD Fund), Danish Rheumatism Association, Danish Council of Radiographers, and UCL University College.

The authors, their immediate families, and any research foundations with which they are affiliated have not received any financial payments or other benefits from any commercial entity related to the subject of this article.

References

- Boonstra AM, Schiphorst Preuper HR, Reneman MF, Posthumus JB, Stewart RE. Reliability and validity of the visual analogue scale for disability in patients with chronic musculoskeletal pain. *Int J Rehabil Res* 2008;31:165–9. <https://doi.org/10.1097/MRR.0b013e3282f0f93>.
- Brage K, Hjarbaek J, Kjaer P, Ingwersen KG, Juul-Kristensen B. Ultrasonic strain elastography for detecting abnormalities in the supraspinatus tendon: an intra- and inter-rater reliability study. *BMJ Open* 2019;9:e027725. <https://doi.org/10.1136/bmjopen-2018-027725>.
- Capalbo E, Peli M, Stradiotti P. Sonoelastography of the distal part of the Achilles tendon in asymptomatic volunteers: correlation with anthropometric data, ultrasound findings and reproducibility of the method. *Radiol Med* 2016;121:667–74. <https://doi.org/10.1007/s11547-016-0642-5>.
- Cosgrove D, Piscaglia F, Bamber J, Bojunga J, Correas JM, Gilja OH, et al. EFSUMB guidelines and recommendations on the clinical use of ultrasound elastography. Part 2: clinical applications. *Ultraschall Med* 2013;34:238–53. <https://doi.org/10.1055/s-0033-1335375>.
- De Zordo T, Fink C, Feuchtner GM, Smekal V, Reindl M, Klauser AS. Real-time sonoelastography findings in healthy Achilles tendons. *AJR Am J Roentgenol* 2009;193:W134–8. <https://doi.org/10.2214/ajr.08.1843>.
- Dierckx R, Bron C, Dorrestijn O, Meskers C, Naber R, de Ruyter T, et al. Guideline for diagnosis and treatment of subacromial pain syndrome: a multidisciplinary review by the Dutch Orthopaedic Association. *Acta Orthop* 2014;85:314–22. <https://doi.org/10.3109/17453674.2014.920991>.
- Dietrich CF, Barr RG, Farrokh A, Dighe M, Hocke M, Jenson C, et al. Strain elastography—how to do it? *Ultrasound Int Open* 2017;3:E137–49. <https://doi.org/10.1055/s-0043-119412>.
- Garra BS. Elastography: history, principles, and technique comparison. *Abdom Imaging* 2015;40:680–97. <https://doi.org/10.1007/s00261-014-0305-8>.
- Hawkins RJ, Kennedy JC. Impingement syndrome in athletes. *Am J Sports Med* 1980;8:151–8.
- Ingwersen KG, Hjarbaek J, Eshøj H, Larsen CM, Vobbe JW, Juul-Kristensen B. Ultrasound assessment for grading structural tendon changes in supraspinatus tendinopathy: an inter-rater reliability study. *BMJ Open* 2016;6:e011746. <https://doi.org/10.1136/bmjopen-2016-011746>.
- Jobe FW, Jobe CM. Painful athletic injuries of the shoulder. *Clin Orthop Relat Res* 1983;117–24.
- Kelly BT, Kadrmaz WR, Speer KP. The manual muscle examination for rotator cuff strength. An electromyographic investigation. *Am J Sports Med* 1996;24:581–8.
- Kelly SM, Brittle N, Allen GM. The value of physical tests for subacromial impingement syndrome: a study of diagnostic accuracy. *Clin Rehabil* 2010;24:149–58. <https://doi.org/10.1177/0269215509346103>.
- Kitis A, Celik E, Aslan UB, Zencir M. DASH questionnaire for the analysis of musculoskeletal symptoms in industry workers: a validity and reliability study. *Appl Ergon* 2009;40:251–5. <https://doi.org/10.1016/j.apergo.2008.04.005>.
- Klauser AS, Faschingbauer R, Jaschke WR. Is sonoelastography of value in assessing tendons? *Semin Musculoskelet Radiol* 2010;14:323–33. <https://doi.org/10.1055/s-0030-1254521>.
- Klauser AS, Miyamoto H, Tamegger M, Faschingbauer R, Moriggl B, Klima G, et al. Achilles tendon assessed with sonoelastography: histologic agreement. *Radiology* 2013;267:837–42. <https://doi.org/10.1148/radiol.13121936>.
- Kocyigit F, Kuyucu E, Kocyigit A, Herek DT, Savkin R, Aslan UB. Investigation of biomechanical characteristics of intact supraspinatus tendons in subacromial impingement syndrome: a cross-sectional study with real-time sonoelastography. *Am J Phys Med Rehabil* 2016;95:588–96. <https://doi.org/10.1097/phm.0000000000000450>.
- Lee SU, Joo SY, Kim SK, Lee SH, Park SR, Jeong C. Real-time sonoelastography in the diagnosis of rotator cuff tendinopathy. *J Shoulder Elbow Surg* 2016;25:723–9. <https://doi.org/10.1016/j.jse.2015.10.019>.
- Luime JJ, Koes BW, Hendriksen IJ, Burdorf A, Verhagen AP, Miedema HS, et al. Prevalence and incidence of shoulder pain in the general population; a systematic review. *Scand J Rheumatol* 2004;33:73–81. <https://doi.org/10.1080/03009740310004667>.
- MacDermid JC, Ramos J, Drosdowech D, Faber K, Patterson S. The impact of rotator cuff pathology on isometric and isokinetic strength, function, and quality of life. *J Shoulder Elbow Surg* 2004;13:593–8. <https://doi.org/10.1016/j.jse.2004.03.009>.
- Mokkink LB, Terwee CB, Patrick DL, Alonso J, Stratford PW, Knol DL, et al. The COSMIN checklist for assessing the methodological quality of studies on measurement properties of health status measurement instruments: an international Delphi study. *Qual Life Res* 2010;19:539–49. <https://doi.org/10.1007/s11136-010-9606-8>.
- Muraki T, Ishikawa H, Morise S, Yamamoto N, Sano H, Itoi E, et al. Ultrasound elastography-based assessment of the elasticity of the supraspinatus muscle and tendon during muscle contraction. *J Shoulder Elbow Surg* 2015;24:120–6. <https://doi.org/10.1016/j.jse.2014.04.012>.
- Neer CS II, Welsh RP. The shoulder in sports. *Orthop Clin North Am* 1977;8:583–91.
- Norman R, Cronin P, Viney R, King M, Street D, Ratcliffe J. International comparisons in valuing EQ-5D health states: a review and analysis. *Value Health* 2009;12:1194–200. <https://doi.org/10.1111/j.1524-4733.2009.00581.x>.
- Pesquer L, Borghol S, Meyer P, Ropars M, Dallaudiere B, Abadie P. Multimodality imaging of subacromial impingement syndrome. *Skeletal Radiol* 2018;47:923–37. <https://doi.org/10.1007/s00256-018-2875-y>.
- Prado-Costa R, Rebelo J, Monteiro-Barroso J, Preto AS. Ultrasound elastography: compression elastography and shear-wave elastography in the assessment of tendon injury. *Insights Imaging* 2018;9:791–814. <https://doi.org/10.1007/s13244-018-0642-1>.
- Sein ML, Walton J, Linklater J, Harris C, Dugal T, Appleyard R, et al. Reliability of MRI assessment of supraspinatus tendinopathy. *Br J Sports Med* 2007;41:e9. <https://doi.org/10.1136/bjism.2006.034421>.
- Seo JB, Yoo JS, Ryu JW. Sonoelastography findings of supraspinatus tendon in rotator cuff tendinopathy without tear: comparison with magnetic resonance images and conventional ultrasonography. *J Ultrasound* 2015;18:143–9. <https://doi.org/10.1007/s40477-014-0148-8>.
- Sharma P, Maffulli N. Biology of tendon injury: healing, modeling and remodeling. *J Musculoskelet Neuronal Interact* 2006;6:181–90.
- Teunis T, Lubberts B, Reilly BT, Ring D. A systematic review and pooled analysis of the prevalence of rotator cuff disease with increasing age. *J Shoulder Elbow Surg* 2014;23:1913–21. <https://doi.org/10.1016/j.jse.2014.08.001>.
- Tudisco C, Bisicchia S, Stefanini M, Antonicoli M, Masala S, Simonetti G. Tendon quality in small unilateral supraspinatus tendon tears. Real-time sonoelastography correlates with clinical findings. *Knee Surg Sports Traumatol Arthrosc* 2015;23:393–8. <https://doi.org/10.1007/s00167-013-2551-7>.
- van der Windt DA, Koes BW, de Jong BA, Bouter LM. Shoulder disorders in general practice: incidence, patient characteristics, and management. *Ann Rheum Dis* 1995;54:959–64.
- Vasishtha A, Kelkar A, Joshi P, Hapse R. The value of sonoelastography in the diagnosis of supraspinatus tendinopathy—a comparison study. *Br J Radiol* 2019;92:20180951. <https://doi.org/10.1259/bjr.20180951>.
- von Elm E, Altman DG, Egger M, Pocock SJ, Gøtzsche PC, Vandenbroucke JP. The Strengthening of Reporting of Observational Studies in Epidemiology (STROBE) statement: guidelines for reporting observational studies. *Int J Surg* 2014;12:1495–9. <https://doi.org/10.1016/j.ijsu.2014.07.013>.