

Wound Healing Process After Thermomechanical Skin Ablation

Kokolakis, Georgios; von Grawert, Leonie; Ulrich, Martina; Lademann, Juergen; Zuberbier, Torsten; Hofmann, Maja A.

Published in:
Lasers in Surgery and Medicine

DOI:
10.1002/lsm.23213

Publication date:
2020

Document version:
Final published version

Document license:
CC BY-NC-ND

Citation for pulished version (APA):
Kokolakis, G., von Grawert, L., Ulrich, M., Lademann, J., Zuberbier, T., & Hofmann, M. A. (2020). Wound Healing Process After Thermomechanical Skin Ablation. *Lasers in Surgery and Medicine*, 52(8), 730-734. <https://doi.org/10.1002/lsm.23213>

Go to publication entry in University of Southern Denmark's Research Portal

Terms of use

This work is brought to you by the University of Southern Denmark.
Unless otherwise specified it has been shared according to the terms for self-archiving.
If no other license is stated, these terms apply:

- You may download this work for personal use only.
- You may not further distribute the material or use it for any profit-making activity or commercial gain
- You may freely distribute the URL identifying this open access version

If you believe that this document breaches copyright please contact us providing details and we will investigate your claim.
Please direct all enquiries to puresupport@bib.sdu.dk

Wound Healing Process After Thermomechanical Skin Ablation

Georgios Kokolakis,¹ Leonie von Grawert,¹ Martina Ulrich,² Juergen Lademann,¹ Torsten Zuberbier,¹ and Maja A. Hofmann^{1,3*}

¹Department of Dermatology, Venereology and Allergology, Charité Universitätsmedizin-Berlin, Berlin, Germany

²Dermatologie am Regierungsviertel / Collegium Medicum Berlin GmbH, Berlin, Germany

³Department of Dermatology, University of Southern Denmark, Odense, Denmark

Background and Objectives: Energy-based devices have been widely applied for skin ablation. A novel ablation technique based on thermomechanical principles (Tixel[®]) has been recently developed. The aim of this study was to examine the wound-healing process and clinical aspects after thermomechanical skin ablation.

Study Design/Materials and Methods: Six female participants were treated with Tixel[®] on healthy skin of the dorsal side of the right forearm in a single session with a 600 µm protrusion and 12 milliseconds pulse. The treated area was examined with confocal laser scanning microscopy on day 1, 2, 7, and 14 after treatment. Clinical symptoms were evaluated at the same time-points.

Results: All patients developed erythema and mild edema on the treated areas, which completely disappeared within 14 days. No post-inflammatory hyperpigmentation or scarring was observed. Thermomechanical skin ablation resulted in the formation of homogeneous micro-ablation zones. Two weeks after ablation, the honeycomb patterns of the epidermis in all examined layers was thoroughly restored. Thus, wound-healing was completed.

Conclusions: Wound healing after thermomechanical skin ablation is much faster compared with other fractionated ablation methods. Treatment intervals of 2–4 weeks could be recommended. *Lasers Surg. Med.* © 2020 The Authors. *Lasers in Surgery and Medicine* published by Wiley Periodicals, Inc.

Key words: thermomechanical skin ablation; Tixel[®]; wound-healing

Several ablative and non-ablative laser devices have been developed to improve skin laxity in the last decade, providing physicians with a wide palette of treatment options.

Currently, ablative fractionated CO₂ or Erbium:Yag lasers and bipolar radiofrequency are the most commonly applied techniques [2,3]. Novel technologies have also emerged that use sources of energy other than light, such as high-intensity focused ultrasound [4].

In the last few years, the development of a new technology based on thermomechanical principles offers a new treatment modality. A precise thermal energy is fractionally transferred to the skin creating an array of microchannels, minimizing downtime, and side effects compared with other fractional skin ablation techniques [5,6].

Confocal laser scanning microscopy (CLSM) is a non-invasive device, which visualizes the superficial layers of the skin *in vivo* in real-time. CLSM allows very detailed imaging with almost histopathological resolution of the epidermis and papillary dermis. The penetration depth is about 250 nm. CLSM was chosen to analyze the wound-healing process, as it is a non-invasive device able to regularly evaluate deeper skin layers. Therefore, the wound-healing process can be monitored over time without the need of surgical intervention [7].

The aim of this proof-of-concept trial was the investigation of the underlying wound-healing processes after skin ablation with thermomechanical ablation (TMA) and their correlation with clinical aspects.

INTRODUCTION

Skin ablation employing energy-based devices has increasingly attracted interest in the last few years. Not only for cosmetic purposes like antiaging, resurfacing, or treating scars but also for therapeutic applications, skin ablation is a well-established efficacious procedure. Side effects including thermal injury, crusting, long-lasting erythema, or hyperpigmentation may prolong the healing process [1]. Dividing the energy into fractions ensures deep dermal penetration of the energy with minimal affection of the epidermis. Thus, rapid recovery times are achieved compared with traditional ablative lasers [2].

This is an open access article under the terms of the Creative Commons Attribution-NonCommercial-NoDerivs License, which permits use and distribution in any medium, provided the original work is properly cited, the use is non-commercial and no modifications or adaptations are made.

Conflict of Interest Disclosures: All authors have completed and submitted the ICMJE Form for Disclosure of Potential Conflicts of Interest and none were reported.

*Correspondence to: Ass. Prof. Maja Hofmann, Department of Dermatology, Venereology and Allergology, Charité, Universitätsmedizin-Berlin, Charitéplatz 1, 10117 Berlin, Germany. E-mail: maja.hofmann@charite.de

Accepted 25 December 2019

Published online 00 Month 2020 in Wiley Online Library (wileyonlinelibrary.com).

DOI 10.1002/lsm.23213

MATERIALS AND METHODS

Patients

In total, six healthy female participants aged 32 ± 3.8 years (mean \pm standard deviation [SD]) and of a Fitzpatrick skin type I-III were included in the trial. Skin conditions affecting the evaluation of the Tixel effects, skin malignancy, previous laser, radiofrequency (RF) or peeling treatments of the treated area were criteria for exclusion. One single TMA treatment of a 10×10 mm area of healthy skin on the dorsal side of the right forearm was applied. Use of topical products prior and after the procedure was not allowed. Clinical assessment of the treated areas with special interest on erythema, edema, crusting, pigmentation changes and scars was performed at day 1 (directly after the treatment), 2, 7, and 14 after treatment. Additionally, the level of pain was estimated using the pain visual analogue scale (0-10) at the same time-points.

The Ethics Committee of the Charité Universitätsmedizin-Berlin approved the protocol. Written informed consent was obtained from all patients. Study procedures were conducted according to the Principles of the Declaration of Helsinki.

Thermomechanical Ablation

Fractionated ablation of the skin was performed by means of an 81-pin thermomechanical system, which applies a Titanium tip (Tixel; Novoxel, Germany). The tip of the 1 cm^2 total surface with 9×9 pins is highly heated to 400°C and ablation occurs through the quick contact of the preheated tip directly onto the skin surface. The penetration depth (protrusion time), as well as the pulse duration, can be individually adjusted. Either a single or double-shot is also possible. For standardization reasons in this study, the protrusion time was adjusted to $600 \mu\text{m}$ and the pulse duration was set to 12 milliseconds as a single shot. These settings represent the typical ones commonly used for skin ablation in daily practice.

Confocal Laser Scanning Microscopy

For the estimation of the distribution and the size of the pores caused by the TMA as well as for the microscopic investigation of the wound-healing processes of the treated areas, CLSM was employed.

In brief, CLSM uses laser as a source of monochromatic coherent light and through reflection facilitates the

non-interventional histological detection of cellular and sub-cellular structures of the skin. The laser beam passes through a splitter, a scanning and focusing optical lens and a skin contact device [8].

In this trial, CLSM was applied at day 1 (directly after the treatment), 2, 7, and 14 after treatment using VivaScope 1500 (Mavig, Munich, Germany).

The diameter of the microscopic ablation zone (MAZ) was measured at three depth levels: epidermis, dermoepidermal junction (DEJ) and papillary dermis. As previously published, for standardization purposes, the measurements were performed in 10–30, 50–70, and 90–100 μm for epidermis, DEJ, and papillary dermis, respectively, using VivaStack (Mavig) [9].

Statistical Analysis

The non-parametric Wilcoxon test was applied for the pairwise comparisons of the MAZ diameter measurements between and within the time-points; $P < 0.05$ was considered statistically significant. Outliers were excluded from the analysis. All values were entered in Microsoft Excel 2013 (Microsoft Corporation, Redmond WA), USA and analyzed with IBM SPSS Statistics Version 25 (IBM Corp., Armonk, NY).

RESULTS

Clinical Evaluation

Participants were clinically examined at day 1, 2, 7, and 14 for therapy-related complications of the treated area. All patients developed erythema and mild edema on the treated areas directly after the ablation. After 1 day, five of six patients developed crusts, whereas erythema and edema persisted. One week after skin ablation, the crusts almost disappeared. Erythema was still notably present but no edema was recognized. At the last time-point, treated skin was completely healed. In 2/6 patients, residual erythema was still detected. In none of the patients, crusts could be seen anymore (Fig. 1).

Evaluation of Pain

Skin ablation using TMA was well tolerated by all patients. Neither local anesthetics nor skin surface cooling were applied before or after the treatment. During the application on the skin, patients described a

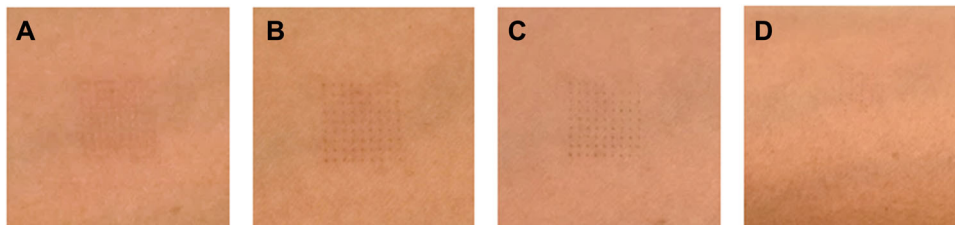


Fig. 1. Clinical manifestations of ablation area at day 1, 2, 7, and 14. (A) Edema and mild erythema directly after ablation. (B) Persistent erythema, edema, and crusts after 2 days. (C) Discrete erythema 1 week after ablation. (D) Complete remission of clinical signs 2 weeks after ablation.

mild-to-moderate pain of average 4 ± 1.9 in VAS pain. No further pain has been reported after the procedure.

Homogeneous Distribution of MAZ

First, we observed the distribution pattern of the MAZ. Like other fractionated skin ablation techniques, for example, bipolar radiofrequency or fractionated laser [3,9], TMA resulted in a homogenous distribution of 81 MAZ in a 10×10 mm area. MAZ were formed in a quadratic pattern with a regular distance. Between the MAZ skin appeared intact (Fig. 2M).

Microscopic Morphology Changes

Directly after skin ablation (day 1), MAZ are sharply defined as well-demarcated round epidermal and subepidermal defects without detection of any cell structures. Reflectance of deeper structures of DEJ and the papillary dermis could also be observed (Fig. 2A–C).

After 1 day, the beginning of the granulation process can be detected in all three examined levels. Islands of fibrinous tissue plunging in from the sites of the MAZ could be most prominently recognized in the papillary dermis, where regenerated tissue covers almost completely the defect area. Small round bright cells and

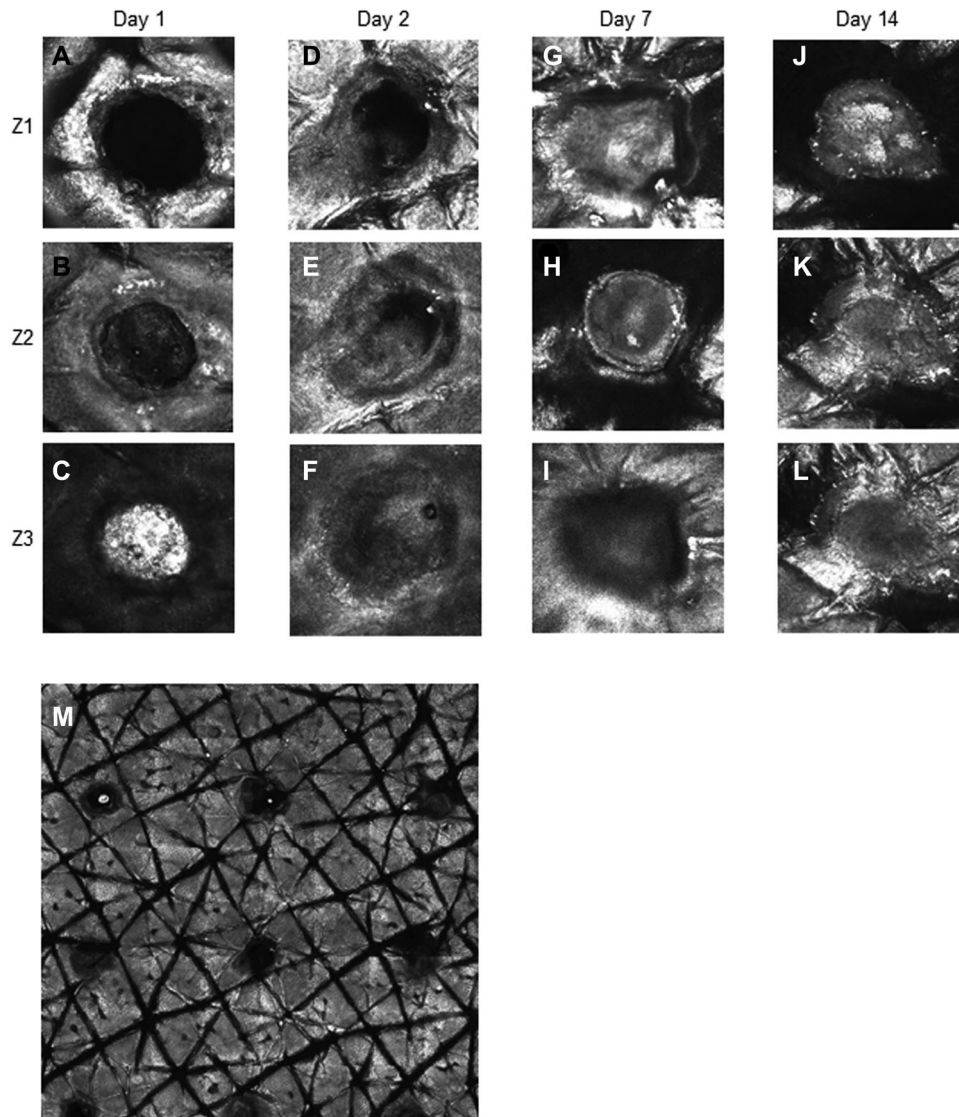


Fig. 2. (A–L) Confocal laser scanning microscopy (CLSM) scans of epidermis (Z1), dermoepidermal junction (Z2) and upper dermis (Z3) in horizontal sections at day 1, 2, 7, and 14 of treatment. Sharply defined round epidermal and subepidermal defects directly after ablation and complete restoration of honeycomb pattern after 14 days. (M) CLSM ViVaStack image of the treated area showing a homogeneous pattern of well-demarcated microscopic ablation zone (MAZ) directly after ablation.

diffuse edema surrounding MAZ indicate the inflammatory phase (Fig. 2D–F).

On the upper epidermal layer, as re-epithelization begins, the typical honeycomb pattern is almost completely reformed at day 7, whereas, in the deeper layers, low refractile amorphous tissue covers the total area of the defect (Fig. 2G–I).

On day 14, MAZ is completely re-epithelized in all three examined levels. The typical honeycomb pattern is thoroughly restored not only in the epidermis but also in the DEJ and papillary dermis level. Epidermal refractility is obviously higher all over the MAZ surface in all three levels (Fig. 2J–L).

Size of MAZ

As a consequence of the dynamic of wound-healing as observed in CLSM, a reduction of the diameter of MAZ should be expected. To clarify this assumption, we measured the diameter of the pores at the three levels as described above (Z1, Z2, and Z3) at all time-points. Interestingly, the diameter of MAZ did not significantly decrease over the observation time, with the exception of the Z3 level at day 7, where it reached a significant decrease compared with baseline ($P = 0.043$) (Fig. 3). Even if MAZ are filled with extracellular material during the healing process, they remain recognizable and stable in size.

DISCUSSION

Micro-invasive skin treatments have become more popular in the last few years. However, the development of new technologies with shortened downtime and reduced post-inflammatory hyperpigmentation (PIH) is needed. In particular, in the case of fractionated CO₂ lasers, a recovery time of up to 1 week and post-treatment erythema for longer than 4 weeks have been described [10]. Moreover, PIH has been reported to be more frequent in ablative fractionated CO₂ lasers depending on the dosages applied, and can occur in 20–92.3% of the patients [11].

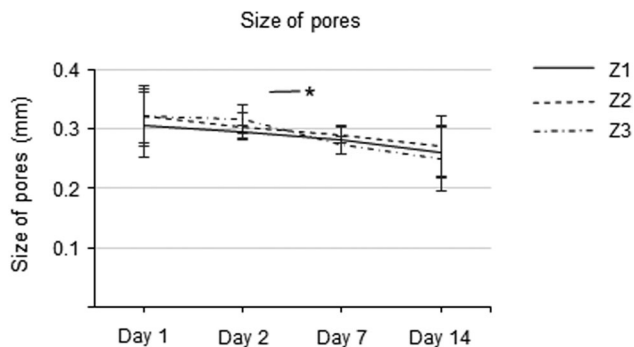


Fig. 3. Diameter of microscopic ablation zone (MAZ) at epidermis (Z1), dermoepidermal junction (Z2), and dermis (Z3) level at day 1 and after 2, 7, and 14 days of treatment. No statistically significant change of the size of pores observed between the time-points and within the same time-point, except in the Z1 level between day 2 and 7.

New devices providing the same efficacy of fractionated laser devices but with less side effects are required. As the process of wound healing is a crucial step to achieve optimal skin remodeling, in this proof-of-concept study, we aimed to examine the microscopic changes occurring during wound-healing after healthy skin ablation with TMA, an innovative skin ablation technology. Additionally, we monitored the clinical manifestations, tolerance and side effects on healthy skin.

The TMA occurs through high heated pins of a metal plate coming into short contact with the skin surface resulting in a fractionated pattern of ablation as known from other light or energy-based devices. TMA revolutionized the field of fractionated devices especially in dark skin types as no chromophores are targeted. The wound-healing procedures occurring after TMA skin ablation resembles models already known from fractional CO₂ laser or bipolar ablative radio frequencies [3,9].

Besides skin ablation, TMA causing a low-energy thermal decomposition of the stratum corneum can enhance the transepidermal penetration of substances [6]; recently proved for botulinum toxin and 5-aminolevulinic-acid [12,13]. These findings, showing an increased permeability of the epidermis after TMA, could maybe be extrapolated for aesthetic applications, like platelet-rich-plasma treatments.

Similarly, to RF, the production of fibrinous tissue begins from the sides of MAZ and presents an upward dynamic beginning from the DEJ heading up to the epidermis. However, the honeycomb pattern of the epidermis is restored much faster. In TMA, we observed a completed honeycomb pattern already after 14 days. In the case of CO₂ laser, 100% and 89.5% of skin damage was still visible on day 21 after ablation when treated with high or low dosage respectively [9]. In RF, 14 days after treatment the subepidermal damage could also be seen in all treated patients [3].

A limitation when using CLSM is incapability for measuring the collagen content in the skin. Collagen is the most abundant protein in human skin and it has been described to be possibly used as biomarker for skin regeneration [14]. Moreover, this proof-of-concept study lacks information about cytokine levels and expression of heat shock proteins and other factors that affect wound-healing and have already been examined following CO₂ fractional laser ablation [15]. Further studies are required to deeply understand the molecular mechanisms following this unique thermoablative technique.

In a recent publication, it could be shown that collagen plays a crucial role in the wound-healing process in acne scars after fractionated CO₂ laser treatment analysed by Raman spectroscopy [16]. A histological study in patients after bipolar RF revealed new collagen and elastin deposition in the treated areas [17]. Regarding TMA, also a histopathological study similarly revealed new collagen formation in the dermis after 7 days of treatment [5]. As TMA also initiated the wound-healing process like the fractionated CO₂ laser, it would be of interest to investigate if there is a difference in the collagen content after the different ablative fractionated systems.

TMA was well tolerated by the patients and only minor skin symptoms were observed. Compared with other skin ablation techniques, like fractionated CO₂ laser, symptoms were minor in intensity and lasted shorter. Similar to already published data with bipolar ablative radio frequencies, TMA caused no pigmentation abnormalities on the treated areas. Pain during treatment was also milder in comparison with CO₂ laser, where local or forced cold air anesthesia was required to achieve similar VAS scores during treatment [18]. Even when comparing with intralesional treatment of keloids with the combination of triamcinolone and 5-fluorouracil (5FU), a lower pain score was reported using TMA [19]. Thus, TMA could be suitable for sensible populations. In a retrospective study, pediatric hypertrophic burn scars were treated with Tixel for transdermal delivery of a topical solution containing triamcinolone and 5FU [20].

As expected, there are limitations in our study. The number of treated patients was restricted. However, the design was considered as a proof-of-concept study with a new technology, compared to already existing data for other fractionated devices. Although the number of the participants of this study is fairly limited, a similar wound-healing model in all patients could be observed, providing evidence for the underlying processes after TMA. Furthermore, only one setting was applied, which, however, represents the common clinical application.

CONCLUSION

In conclusion, as the wound-healing process after TMA is much faster, the recovery time is significantly minimized compared to other ablative techniques. Sessions shorter than 4 weeks could be clinically recommended, but they should not be further reduced than 2 weeks.

REFERENCES

- Riggs K, Keller M, Humphreys TR. Ablative laser resurfacing: High-energy pulsed carbon dioxide and erbium:yttrium-aluminum-garnet. *Clin Dermatol* 2007;25(5):462–473.
- Tierney EP, Eisen RF, Hanke CW. Fractionated CO₂ laser skin rejuvenation. *Dermatol Ther* 2011;24(1):41–53.
- Kokolakis G, von Eichel L, Ulrich M, Lademann J, Zuberbier T, Hofmann MA. Kinetics and tissue repair process following fractional bipolar radiofrequency treatment. *J Cosmet Laser Ther* 2019;21(2):71–75.
- Vachiramon V, Jurairattanaporn N, Harnchoowong S, Chayavichitsilp P. Non-invasive high-intensity focused ultrasound for UV-induced hyperpigmentation in Fitzpatrick skin types III and IV: A prospective, randomized, controlled, evaluator-blinded trial. *Lasers Med Sci* 2018;33(2):361–367.
- Elman M, Fournier N, Barneon G, Bernstein EF, Lask G. Fractional treatment of aging skin with Tixel, a clinical and histological evaluation. *J Cosmet Laser Ther* 2016;18(1):31–37.
- Sintov AC, Hofmann MA. A novel thermo-mechanical system enhanced transdermal delivery of hydrophilic active agents by fractional ablation. *Int J Pharm* 2016;511(2):821–830.
- Srivastava R, Reilly C, Francisco G, Bhatti H, Rao BK. Life of a wound: Serial documentation of wound healing after shave removal using reflectance confocal microscopy. *J Drugs Dermatol* 2019;18(5):472–474.
- Calzavara-Pinton P, Longo C, Venturini M, Sala R, Pellacani G. Reflectance confocal microscopy for in vivo skin imaging. *Photochem Photobiol* 2008;84(6):1421–1430.
- Sattler EC, Poloczek K, Kastle R, Welzel J. Confocal laser scanning microscopy and optical coherence tomography for the evaluation of the kinetics and quantification of wound healing after fractional laser therapy. *J Am Acad Dermatol* 2013;69(4):e165–e173.
- Chan NP, Ho SG, Yeung CK, Shek SY, Chan HH. Fractional ablative carbon dioxide laser resurfacing for skin rejuvenation and acne scars in Asians. *Lasers Surg Med* 2010;42(9):615–623.
- Lee HS, Lee DH, Won CH, et al. Fractional rejuvenation using a novel bipolar radiofrequency system in Asian skin. *Dermatol Surg* 2011;37(11):1611–1619.
- Friedman O, Koren A, Niv R, Mehrabi JN, Artzi O. The toxic edge-A novel treatment for refractory erythema and flushing of rosacea. *Lasers Surg Med* 2019;51(4):325–331.
- Shavit R, Dierickx C. A new method for percutaneous drug delivery by thermo-mechanical fractional injury. *Lasers Surg Med* 2019. <https://doi.org/10.1002/lsm.23125>. [Epub ahead of print].
- Yan W, Liu H, Deng X, et al. Raman spectroscopy enables noninvasive biochemical identification of the collagen regeneration in cutaneous wound healing of diabetic mice treated with MSCs. *Lasers Med Sci* 2017;32(5):1131–1141.
- DeBruiler DM, Blackstone BN, Baumann ME, et al. Inflammatory responses, matrix remodeling, and re-epithelialization after fractional CO₂ laser treatment of scars. *Lasers Surg Med* 2017;49(7):675–685.
- Chiwo FS, Guevara E, Ramírez-Elías MG, et al. Use of Raman spectroscopy in the assessment of skin after CO₂ ablative fractional laser surgery on acne scars. *Skin Res Technol* 2019;25(6):805–809.
- Hantash BM, Ubeid AA, Chang H, Kafi R, Renton B. Bipolar fractional radiofrequency treatment induces neocollagenesis and neocollagenesis. *Lasers Surg Med* 2009;41(1):1–9.
- Sari E, Bakar B. Which is more effective for pain relief during fractionated carbon dioxide laser treatment: EMLA cream or forced cold air anesthesia? *J Cosmet Laser Ther* 2018;20(1):34–40.
- Artzi O, Koren A, Niv R, Mehrabi JN, Friedman O. The scar bane, without the pain: A new approach in the treatment of elevated scars: Thermomechanical delivery of topical triamcinolone acetonide and 5-fluorouracil. *Dermatol Ther (Heidelb)* 2019;9(2):321–326.
- Artzi O, Koren A, Niv R, Mehrabi JN, Mashiah J, Friedman O. A new approach in the treatment of pediatric hypertrophic burn scars: Tixel-associated topical triamcinolone acetonide and 5-fluorouracil delivery. *J Cosmet Dermatol* 2019. <https://doi.org/10.1111/jocd.13192>. [Epub ahead of print].