

**Third degree atrioventricular block associated with treatment with rivastigmine transdermal patch**

Knudtzen, Fredrikke C; Christophersen, Thomas B

*Published in:*  
Journal of Geriatric Cardiology

*DOI:*  
10.3969/j.issn.1671-5411.2013.01.017

*Publication date:*  
2013

*Document version:*  
Final published version

*Document license:*  
CC BY-NC-SA

*Citation for pulished version (APA):*  
Knudtzen, F. C., & Christophersen, T. B. (2013). Third degree atrioventricular block associated with treatment with rivastigmine transdermal patch. *Journal of Geriatric Cardiology*, 10(1), 113-115.  
<https://doi.org/10.3969/j.issn.1671-5411.2013.01.017>

Go to publication entry in University of Southern Denmark's Research Portal

**Terms of use**

This work is brought to you by the University of Southern Denmark.  
Unless otherwise specified it has been shared according to the terms for self-archiving.  
If no other license is stated, these terms apply:

- You may download this work for personal use only.
- You may not further distribute the material or use it for any profit-making activity or commercial gain
- You may freely distribute the URL identifying this open access version

If you believe that this document breaches copyright please contact us providing details and we will investigate your claim.  
Please direct all enquiries to [puresupport@bib.sdu.dk](mailto:puresupport@bib.sdu.dk)



## Third degree atrioventricular block associated with treatment with rivastigmine transdermal patch

Fredrikke C. Knudtzen, Thomas B. Christophersen

Department of Internal Medicine, OUH Svendborg Hospital, Valdemarsgade 53, 5700 Svendborg, Denmark

### Abstract

Rivastigmine transdermal patch is indicated for patients with Alzheimer's disease and dementia with Parkinson's disease. Rivastigmine, an acetylcholinesterase inhibitor, has several common adverse effects, mainly involving the gastrointestinal tract, but few cardiovascular adverse effects have been reported. This report presents two cases of patients presenting with 3<sup>rd</sup> degree atrioventricular block. Both patients were treated with the acetylcholinesterase inhibitor, rivastigmine. In one case, the patient reverted to normal sinus rhythm following the discontinuation of rivastigmine, and the atrioventricular block reappeared after rivastigmine was reinstated. In the other case, the atrioventricular block did not revert and the patient required a permanent pacemaker. Both bradycardia and syncope have previously been reported as adverse events in patients treated with acetylcholinesterase inhibitors. However, the type of bradycardia and the etiology of the syncope are rarely specified. Rivastigmine, and other acetylcholinesterase inhibitors, are widely used in the pharmacological treatment of Alzheimer's disease. We recommend that physicians are vigilant of possible warning signs, such as dizziness, syncope and bradycardia.

*J Geriatr Cardiol* 2013; 10: 113–115. doi: 10.3969/j.issn.1671-5411.2013.01.017

**Keywords:** Atrioventricular block; Rivastigmine; Acetylcholinesterase inhibitors; Alzheimer's disease

## 1 Introduction

Alzheimer's disease (AD) is a progressive, neurodegenerative disorder, characterized by reduced cognition, behavior and activities of daily life. AD is the most frequent form of dementia worldwide. The primary pharmacological treatment for AD is acetylcholinesterase inhibitors (AChEIs), such as donepezil, galantamine and rivastigmine. AChEIs are indicated for the symptomatic treatment of AD and improvement of cognitive function and reduction of the progressive loss of function in AD patients.<sup>[1,2]</sup> Rivastigmine is also indicated for patients with dementia associated with Parkinson's disease (PD).<sup>[3]</sup> Common adverse effects of AChEIs are nausea, vomiting and diarrhea.<sup>[4]</sup> However, little is known about the potential cardiovascular adverse effects of AChEIs. In this report, we present two cases in which patients treated with rivastigmine transdermal patch are admitted to the coronary care unit with 3<sup>rd</sup> degree atrioventricular block.

## 2 Case report

### 2.1 Case 1

Eighty-eight year old female admitted to the coronary care unit following a two week history of dizziness and shortness of breath. The patient had no history of ischemic heart disease and had no chest pain. Extended history revealed she had experienced two inexplicable falling episodes as well as one syncope in the months prior to admission. The cause of these episodes had not yet been investigated. Electrocardiography (ECG) at admission revealed a third degree atrioventricular block with a heart rate of 25–30 beats/min (Figure 1).

Twenty-four months prior to admission, the patient was diagnosed with AD with paranoid symptoms in a psychiatric outpatient clinic and started treatment with rivastigmine transdermal patch titrated to 9.6 mg/d, as well as mirtazapine and levodopa. The patient was also treated for hypertension with losartan and a thiazide. ECG at the initiation of rivastigmine therapy showed sinus rhythm, with a heart rate of 67 beats/min. There were no signs of ischemia and no atrioventricular conduction delay. Computer tomography (CT) of the brain at time of initiation of rivastigmine was described as normal. The physical examination at admission revealed no positive neurological deficits save for her known cognitive dysfunction. The patient had normal red

**Correspondence to:** Fredrikke C. Knudtzen, MD, Department of Internal Medicine, OUH Svendborg Hospital, Valdemarsgade 53, 5700 Svendborg, Denmark. E-mail: fredrikkeknudtzen@hotmail.com

**Telephone:** +45-63202-000

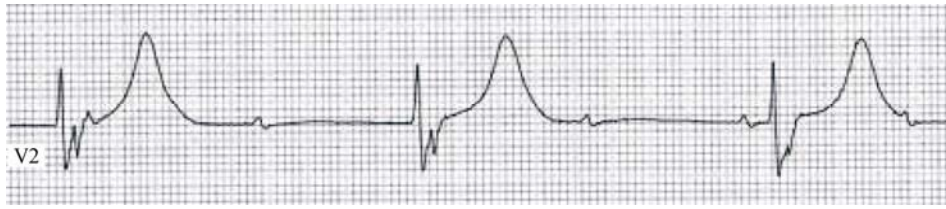
**Fax:** +45-63202-229

**Received:** May 11, 2012

**Revised:** October 29, 2012

**Accepted:** January 29, 2013

**Published online:** March 21, 2013



**Figure 1. Third degree atrioventricular block - Electrocardiogram from the patient in Case 1, showing third degree atrioventricular block.**

and white blood counts, normal creatinine for her age and normal C-reactive protein (CRP) < 10 mg/L. She had slight hyponatremia of 132 mmol/L (normal range 136–146 mmol/L) and hypocalcemia of 1.12 mmol/L (normal range 1.19–1.29 mmol/L) with normal potassium. Thyroid stimulating hormone was normal. Cardiac biomarkers were slightly elevated at admission with a troponin T of 64 ng/L (upper limit of normal 50 ng/L) and a creatine kinase MB (CK-MB) of 8.4  $\mu$ g/L (upper limit of normal 4  $\mu$ g/L). Echocardiography was normal, and the patient was not found a candidate for Coronary Angiography (CAG) due to her general state, and the lack of chest pain. It was concluded by the treating cardiologists that her atrioventricular block was caused by rivastigmine. Rivastigmine was discontinued and the patient received a temporary pacemaker. No other medication was discontinued. After 13 days without resolution of the atrioventricular block, a permanent atrioventricular pacemaker was implanted and the patient was discharged to her own home. Per patient request, rivastigmine was not reinitiated.

## 2.2 Case 2

Seventy-one year old male admitted to the coronary care unit with shortness of breath. The patient had a prior history of stroke, but no history of cardiac disease and had no chest pain. ECG at admission revealed a 3<sup>rd</sup> degree atrioventricular block with a heart rate of 25–35 beats/min. The patient had been diagnosed with PD eight months earlier by a neurologist and started rivastigmine transdermal patch titrated to 9.6 mg/d, as well as mirtazapine, levodopa and quetiapin with good response. ECG before the initiation of rivastigmine therapy showed sinus rhythm, with a heart rate of 68 beats/min. There were no signs of ischemia and no atrioventricular conduction delay. The patient was followed in a geriatric outpatient clinic and had no known co-morbidities. The patient had normal red and white blood counts, slightly increased creatinine 108  $\mu$ g/L and normal CRP. Electrolytes and thyroid stimulating hormone were normal. Troponin T was normal at admission, but increased slightly to 64 ng/L after 12 h. Echocardiography was normal. Rivastigmine was discontinued and intravenous isoprenaline was initiated. The patient reverted to a normal sinus rhythm. The patient

started low-dose aspirin, but was not a candidate for invasive coronary angiography due to his general and mental state. Following consultations with the patient's family and caregivers, rivastigmine was reinitiated under continuous electrocardiographic monitoring. Atrioventricular block did not reappear and the patient was discharged with rivastigmine treatment. Cardiac follow-up after three months, including echocardiography, was normal. Eighteen months later, the patient was admitted to the medical ward after dizziness and fall, ECG showed 1<sup>st</sup> degree atrioventricular block. The patient was tested positive for orthostatic hypotension, and discharged after seven days. One week following the discharge, the patient was re-admitted to the coronary care unit due to syncope and bradycardia. The ECG revealed a 3<sup>rd</sup> degree atrioventricular block with a heart rate of 30–32 beats/min. The patient had no chest pain, and consecutive measurements of Troponin T were within normal range. The patient received a permanent atrioventricular pacemaker later that day and was discharged the following day.

## 3 Discussion

In third degree atrioventricular block, there is a complete dissociation between the atrial and ventricular heart rhythm. Symptoms of this condition can be syncope, near-syncope, dizziness, shortness of breath or sudden death, but it can also be asymptomatic. Acquired complete atrioventricular block can be caused by a myocardial infarction, several systemic inflammatory, infectious and infiltrative diseases, or it can be triggered by use or overdosing of pharmaceuticals, such as antiarrhythmic drugs, antidepressants and psychopharmaceuticals.<sup>[5]</sup>

We present two cases of complete atrioventricular block in patients receiving therapy with rivastigmine transdermal patch. Rivastigmine is a selective, reversible acetylcholinesterase and butyrylcholinesterase inhibitor, increasing the effects of acetylcholine in cholinergic neurons. Rivastigmine appears to be more selective towards the acetylcholinesterase isoform G1, which is abundant in the cerebral cortex, whereas the inhibition of the G4 isoform, which is predominant in the peripheral skeletal muscles, is less pro-

nounced. It has been suggested that this may minimize peripheral adverse effects, including cardiac events.<sup>[1]</sup> The transdermal formulation of rivastigmine has shown a better tolerability than oral formulation, with less adverse events. This may be due to the more continuous delivery of the drug from the transdermal patch.<sup>[2,6]</sup>

Due to central cholinergic affection, AChEIs may cause adverse cardiac events, such as bradycardia and syncope.<sup>[7]</sup> Usually no discrimination between the different forms of bradycardia is reported. However, these adverse events appear to be rare and, thus, difficult to detect in the pre-registration phase III studies. In a retrospective report, Morganroth *et al.*<sup>[8]</sup> pooled data from four phase III studies in order to describe the electrocardiographic effects of rivastigmine. Complete atrioventricular block was not reported. However, 19 patients on rivastigmine received a permanent pacemaker for unreported indications. Kayrak *et al.*<sup>[9]</sup> reported a case in which a patient on oral rivastigmine presented with complete atrioventricular block, which resolved to normal sinus rhythm after the discontinuation of rivastigmine. Complete atrioventricular block re-emerged with the reinitiation of rivastigmine therapy, indicating a causal effect of rivastigmine. The patient history with syncope and falls in Case 1 indicated a longer history of problems that may have been related to bradycardia. However, no ECG was recorded prior to admission. Both bradycardia and falls have been reported as adverse events of AChEIs treatment<sup>[7]</sup> and in our opinion attending physicians should be vigilant of potentially serious adverse events, which may require intervention, and perform an ECG in patients with these symptoms. In Case 1, the atrioventricular block did not resolve and the patient required a permanent pacemaker. However, drug-induced atrioventricular block may not always resolve spontaneously following the discontinuation of the culprit drug, as reported by Zeltser *et al.*<sup>[10]</sup> Treatment with AChEIs may be resumed following pacemaker implantation, but in this case the patient did not wish to continue the treatment. In Case 2, the atrioventricular block resolved following discontinuation of rivastigmine. Following reinitiation of rivastigmine, the patient developed symptoms of dizziness and syncope and at a later point, the block was rediscovered. Our two cases have scores of three and nine on the Naranjo adverse drug reaction probability scale<sup>[11]</sup> indicating a possible and definite causal relationship, respectively. In both cases, the patients had slightly elevated cardiac biomarker levels indicating myocardial damage at the time of first admission. Elevated troponin levels have been associated to a number of cardiac conditions, such as myocardial infarction, myocarditis, amyloidosis, tachycardia, cardiomyopathy and atrioventricular block.<sup>[12]</sup> In both patients, echocardiography found no evidence of other causative factors, but no inva-

sive examinations were performed. At the second admission of Case 2, the myocardial biomarkers were not elevated. Neither patient received concomitant pharmacological treatment with reported atrioventricular adverse events.

## 4 Conclusion

We present two cases in which pharmacological treatment with rivastigmine transdermal patch may have induced a complete atrioventricular block. This serious adverse event is rarely reported in patients treated with AChEIs and it may be difficult to detect due to low incidence. Therefore, treating physicians should be vigilant of warning signs, such as bradycardia, dizziness and syncope.

## References

- 1 Dhillon S. Rivastigmine transdermal patch: a review of its use in the management of dementia of the Alzheimer's type. *Drugs* 2011; 71: 1209–1231.
- 2 Winblad B, Cummings J, Andreasen N, *et al.* A six-month double-blind, randomized, placebo-controlled study of a transdermal patch in Alzheimer's disease--rivastigmine patch versus capsule. *Int J Geriatr Psychiatry* 2007; 22: 456–467.
- 3 Emre M, Aarsland D, Albanese A, *et al.* Rivastigmine for dementia associated with Parkinson's disease. *N Engl J Med* 2004; 351: 2509–2518.
- 4 Grossberg GT, Olin JT, Somogyi M, *et al.* Dose effects associated with rivastigmine transdermal patch in patients with mild-to-moderate Alzheimer's disease. *Int J Clin Pract* 2011; 65: 465–471.
- 5 Libby P, Bonow RO, Mann DL, *et al.* *Braunwald's Heart Disease: A Textbook of Cardiovascular Medicine*, 8<sup>th</sup> ed.: Saunders, Elsevier: Philadelphia, USA, 2008.
- 6 Blesa R, Ballard C, Orgogozo JM, *et al.* Caregiver preference for rivastigmine patches versus capsules for the treatment of Alzheimer disease. *Neurology* 2007; 69(4 Suppl 1): S23–S28.
- 7 Hernandez RK, Farwell W, Cantor MD, *et al.* Cholinesterase inhibitors and incidence of bradycardia in patients with dementia in the veterans affairs new England healthcare system. *J Am Geriatr Soc* 2009; 57: 1997–2003.
- 8 Morganroth J, Graham S, Hartman R, *et al.* Electrocardiographic effects of rivastigmine. *J Clin Pharmacol* 2002; 42: 558–568.
- 9 Kayrak M, Yazici M, Ayhan SS, *et al.* Complete atrioventricular block associated with rivastigmine therapy. *Am J Health Syst Pharm* 2008; 65: 1051–1053.
- 10 Zeltser D, Justo D, Halkin A, *et al.* Drug-induced atrioventricular block: prognosis after discontinuation of the culprit drug. *J Am Coll Cardiol* 2004; 44: 105–108.
- 11 Naranjo CA, Busto U, Sellers EM, *et al.* A method for estimating the probability of adverse drug reactions. *Clin Pharmacol Ther* 1981; 30: 239–245.
- 12 Thygesen K, Alpert JS, White HD, *et al.* Universal definition of myocardial infarction. *Circulation* 2007; 116: 2634–2653.