



University of Southern Denmark

Does therapy of the primary tumor matter in oligometastatic prostate cancer? A prospective 10-year follow-up study

Poulsen, Mads Hvid; Jakobsen, Jørn Skibsted; Mortensen, Mike Allan; Høilund-Carlsen, Poul Flemming; Lund, Lars

Published in:
Research and Reports in Urology

DOI:
10.2147/RRU.S190140

Publication date:
2019

Document version:
Final published version

Document license:
CC BY-NC

Citation for pulished version (APA):

Poulsen, M. H., Jakobsen, J. S., Mortensen, M. A., Høilund-Carlsen, P. F., & Lund, L. (2019). Does therapy of the primary tumor matter in oligometastatic prostate cancer? A prospective 10-year follow-up study. *Research and Reports in Urology*, 11, 215-221. <https://doi.org/10.2147/RRU.S190140>

Go to publication entry in University of Southern Denmark's Research Portal

Terms of use

This work is brought to you by the University of Southern Denmark.
Unless otherwise specified it has been shared according to the terms for self-archiving.
If no other license is stated, these terms apply:

- You may download this work for personal use only.
- You may not further distribute the material or use it for any profit-making activity or commercial gain
- You may freely distribute the URL identifying this open access version

If you believe that this document breaches copyright please contact us providing details and we will investigate your claim.
Please direct all enquiries to puresupport@bib.sdu.dk

Does therapy of the primary tumor matter in oligometastatic prostate cancer? A prospective 10-year follow-up study

This article was published in the following Dove Press journal:
Research and Reports in Urology

Mads Hvid Poulsen^{1,2}
Jørn Skibsted Jakobsen³
Mike Allan Mortensen^{1,4}
Poul Flemming Højlund-Carlson^{4,5}
Lars Lund^{1,2,4}

¹Department of Urology, Odense University Hospital, Odense, Denmark; ²Academy of Geriatric Cancer Research (AgeCare), Odense University Hospital, Odense, Denmark; ³Department of Urology, Herlev and Gentofte University Hospital, Copenhagen, Denmark; ⁴Department of Clinical Research, University of Southern Denmark, Odense, Denmark; ⁵Department of Nuclear Medicine, Odense University Hospital, Odense, Denmark

Objective: The effect of curative treatment for oligometastatic prostate cancer patients is unsolved, both with regard to morbidity and mortality. With this study, we provide some of the first long-term follow-up data on progression and mortality in oligometastatic prostate cancer patients after curative treatment of their primary tumor.

Methods: A cohort of 210 patients with diagnosed prostate cancer was established between 2008 and 2010. All patients were scheduled for intended curative treatment, and all underwent blinded ¹⁸F-choline positron-emission tomography/computed tomography at inclusion prior to curative treatment. Upon unblinding, 12 patients (6%) were recategorized as being oligometastatic. They had a mean age of 64 years, median prostate-specific antigen of 18 ng/mL, and median Gleason score of 7. Six patients were staged as T3, one T2, and five T1. The patients had a median of one bone metastasis (range 1–2). All underwent intended curative radiotherapy or prostatectomy. Mean follow-up was 10.1 (8.9–11.0) years.

Results: During follow-up of the 12 patients, three (25%) had biochemical recurrence, two developed castration-resistant disease, and one died due to prostate cancer.

Conclusion: Our results suggest that intended curative treatment of the primary tumor in oligometastatic prostate cancer may have a role in highly selected patients.

Keywords: prostate cancer, oligometastases, treatment

Introduction

There is a new paradigm on the horizon regarding the treatment of oligometastatic prostate cancer with a limited number of metastases.¹ The question is whether treatment of the primary tumor matters. Three recent reviews on oligometastatic disease depicted many potential benefits of multimodal treatment, but also pitfalls: lack of data from prospective trials, lack of clear definition of oligometastatic stage, different staging modalities, addition of metastasis directed therapy or not, and the morbidity added by the therapy.^{2–4} The rationale for a more aggressive treatment approach to patients with only a few metastases was described by Helmann et al in 1995.⁵ They suggested that there was an intermediate state in the evolution of the disease, with only a limited number of metastases confined to specific organs. This hypothesis has since been supported by animal studies that described signaling between the primary tumor and the metastases.^{6,7} This implies that aggressive localized treatment may inhibit the metastatic capability of the disease and prove effective in patients with oligometastases.

Treatment of the primary tumor and metastatic sites in patients with oligometastases is well established in other malignancies, eg, colon cancer with liver metastases and primary lung cancer with adrenal metastases.^{8–12} In men with oligometastatic prostate

Correspondence: Mads Hvid Poulsen
Research Unit of Urology, Department for
Urology, Odense University Hospital, 4 JB
Winsløvs Vej, Odense 5000, Denmark
Tel +45 21 765 418
Email mads.poulsen@rsyd.dk

cancer, retrospective studies have found a correlation between treatment of the primary tumor and improvements in morbidity and mortality.²⁻⁴ To date, two randomized clinical trials — STAMPEDE and HORRAD — have been published, and a number are ongoing. The data of the two published trials point are not alike, but they do point toward an effect on survival with addition of therapy to the prostate of oligometastatic prostate cancer patients.^{13,14} In this prospective long-term follow-up study of patients with hormone-naïve prostate cancer and oligometastatic disease defined by ¹⁸F-choline positron-emission tomography (PET)/computed tomography (CT) imaging, we tried to answer the question of whether treatment of the primary tumor matters.

Methods

Patients

Oligometastatic disease was found among 210 patients who had been consecutively included from January 2008 to December 2010 in a prospective study on the value of ¹⁸F-choline PET/CT for lymph-node staging in prostate cancer.¹⁵ All patients had newly diagnosed prostate cancer and were TNM-classified as M0 according to bone scintigraphy or in cases of doubt magnetic resonance imaging (MRI). All patients were scheduled for intended curative therapy, ie, radical prostatectomy or external-beam radiation therapy (EBRT) plus androgen-deprivation therapy (ADT), and all underwent ¹⁸F-choline PET/CT prior to regional lymph-node dissection. ¹⁸F-choline PET/CT results were blinded according to the protocol and thus did not affect or change patient management. All patients met inclusion criteria of Gleason score >6 and/or prostate-specific antigen (PSA) >10 ng/mL and/or T3 cancer. Exclusion criteria were withdrawal of informed consent, TNM stage T4, detection of bone metastases by bone scintigraphy, or prior or active ADT. The study was approved by the Regional Committees on Health Research Ethics for Southern Denmark (S-20070093) and registered at both the Danish Data Protection Agency and ClinicalTrials.gov (NCT00670527). The study was conducted in accordance with the Declaration of Helsinki, all participants gave oral and written informed consent to participate, and all accepted blinding of ¹⁸F-choline PET/CT results. Follow-up continued until March 2019. The authors do not intend to share deidentified participant data.

Treatment and follow-up

During follow-up, the ¹⁸F-Choline PET/CT scans were unblinded, and resulted in reclassification of 12 patients,

due to the finding of bone metastases. These patients were reclassified as M1, due to PET/CT findings. All 12 oligometastatic patients had been treated with curative intent. Radiation was 78 Gy delivered in 39 fractions. ADT together with radiation was 3 years' LHRH therapy for high-risk patients and 6 months' LHRH therapy for intermediate-risk patients. Prostatectomy was performed as an open procedure. Salvage radiation was 60 Gy in 30 fractions, together with 2 years of ADT. Treatment of castration-resistant prostate cancer was continuous ADT with the addition of enzalutamide followed by docetaxel.

Imaging protocol

¹⁸F-choline was produced on the TracerLab MX FDG automated synthesis system via alkylation of dimethylaminoethanol with ¹⁸F-fluorobromomethane.¹⁶ PET/CT data were acquired with a Discovery VCT PET/CT scanner (GE Healthcare, Little Chalfont, UK).¹⁷ Diagnostic CT scans were acquired using in vivo contrast medium from the base of the skull to mid-thigh. PET scans of the same region were obtained with an acquisition time of 2.5 minutes per bed position. CT, PET, and fused PET-CT data were analyzed on a GE Healthcare Advantage Workstation version 4.4. ¹⁸F-choline PET/CT scans were interpreted considering regional and distant metastases and assessed both as CT alone and as PET-CT. Both soft-tissue and bone lesions were detected visually. Lesions were regarded as malignant when they showed high focal intensity, as seen in [Figure 1](#). The first 110 scans were interpreted by a single nuclear medicine specialist and an oncoradiologist, whereas the remaining 100 scans were interpreted by the same nuclear medicine specialist, who is also a CT specialist. Patients fasted for 6 hour before the intravenous administration of radiotracer, each receiving 4 MBq/kg body weight.¹⁸ In all, PET/CT acquisition started approximately 60 minutes postinjection.

Results

The 12 oligometastatic patients had a mean age of 63.9 (53–75) years and median PSA 17 (6–42) ng/mL ([Tables 1](#) and [2](#)). Mean follow-up was 10.1 (8.9–11.0) years. Six patients were staged as T3, one T2, and five T1. Clinical data of the patients did not differ significantly from the whole cohort of 210 patients, who had mean PSA of 20.3, median Gleason score of 7, and 44% of whom were high-risk patients. The majority of the 12 patients had a single bone metastasis located within the axial skeletal, while two patients had two metastases each. An example of a patient with two bone metastases

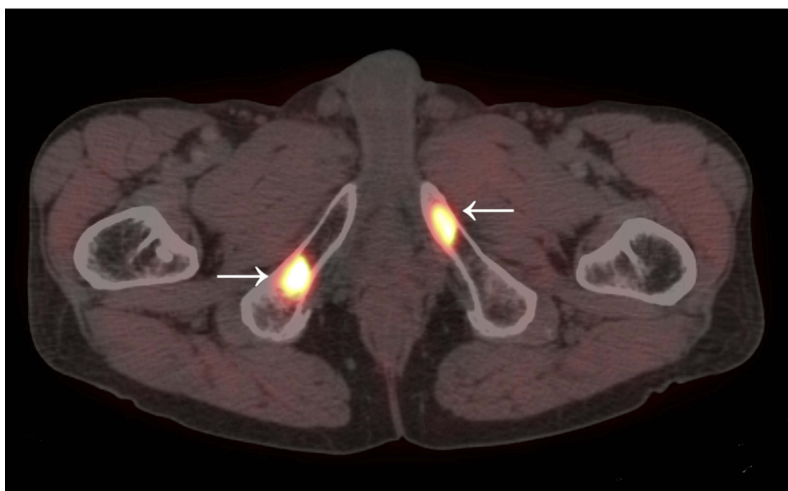


Figure 1 Positron-emission tomography-computed tomography. Hot spots within the os pubis can be seen.

Notes: The patient died due to prostate cancer 8.8 years after his cancer diagnosis. He had received intended curative radiation therapy with 78 Gy and 3 years' androgen-deprivation therapy.

Table 1 Characteristics of the patients

Age (years)	Mean (\pm SD, range)	63.9 (\pm 7.3, 53–75)
Prostate-specific antigen (ng/mL)	Median (range) Mean (\pm SD)	17 (6–42) 18.3 (\pm 12.5)
Clinical stage	T1 T2 T3	5 (41.7%) 1 (8.3%) 6 (50.0%)
Pathological Gleason score	<7 7 >7 Range	2 (16.7%) 7 (58.3%) 3 (25.0%) 5–9
D'Amico risk group	Intermediate High	2 (16.7%) 10 (83.3%)
Treatment	Prostatectomy Radiation + androgen-deprivation therapy	2 (16.7%) 10 (83.3%)

is seen in [Figure 1](#). Ten of these 12 patients (83%) had curative EBRT with 3 years of ADT. Two patients (17%) had a prostatectomy, and one of them was later treated with salvage EBRT without ADT due to recurrence. After salvage treatment, the patient did not progress further. During follow-up, in all three patients (25%) with biochemical recurrence,

two developed castration-resistant disease and one died due to prostate cancer. One patient died due to other causes.

Discussion

The present prospective cohort comprised 12 patients (6%) with oligometastatic prostate cancer identified by ^{18}F -choline

Table 2 Detailed data and follow-up

Patient	Age, years	Gleason score	PSA	T stage	Lymph nodes removed	Bone metastases on PET/CT	Treatment	PSA recurrence	CRPC	Years from diagnosis to CRPC	Death	Death by prostate cancer	Years from diagnosis to death	Years of observation
1	53	9	11	T3a	3	1	Radiation + ADT							11.0
2	62	5	6	T3a	5	1	Radiation + ADT							10.9
3	58	6	7	T3b	3	2	Radiation + ADT							10.8
4	67	7	9	T3b	5	1	Radiation + ADT							10.8
5	74	7	25	T1b	2	2	Radiation + ADT	Yes	Yes	7.0	Yes	Yes	8.8	10.6
6	75	7	40	T2b	10	1	Radiation + ADT	Yes	Yes	9.2	Yes	No	1.8	10.6
7	73	9	18	T1c	8	1	Radiation + ADT	Yes	Yes					10.2
8	54	7	27	T1c	3	1	Prostatectomy + salvage	Yes						9.5
9	63	9	42	T3a	9	1	Radiation + ADT	Yes						9.4
10	60	7	15	T3b	3	1	Radiation + ADT							9.2
11	63	7	10	T1c	2	1	Prostatectomy							9.0
12	65	7	10	T1c	2	1	Radiation + ADT							8.9

Abbreviations: PSA, prostate-specific antigen; PET, positron-emission tomography; CT, computed tomography; CRPC, castration-resistant prostate cancer; ADT, androgen-deprivation therapy.

PET/CT. Among them, we found high long-term progression free survival together with a high prostate cancer-specific survival following curative treatment of the primary tumor. The patients were a part of cohort of 210 who had been enrolled prospectively in a study on lymph-node staging.¹⁵ To our knowledge, this is the first long-term prospective study trying to answer the question of whether intended curative therapy of a primary tumor pays off in this particular type of patient. Our results suggest that it does, but at the same time it raises the question of whether one can rely on findings of next-generation scanners (PET/CT) when they are used for the detection of bone metastases.

In a recent meta-analysis of choline PET/CT for detection of bone metastases in prostate cancer, Shen et al reported pooled sensitivity and specificity on per-patient analysis of 0.87 (95% CI 0.79–0.93) and 0.97 (95% CI 0.93–0.99), respectively, and on per-lesion analysis of 0.83 (95% CI 0.81–0.85) and 0.95 (95% CI 0.94–0.97), respectively.¹⁹ In another study by our group, where we used the same type of scanners and the same ¹⁸F-choline tracer, we obtained similar results for detection of bone metastases — sensitivity and specificity (85% and 91%), positive and negative predictive values of 95% and 75%, respectively, and accuracy of 87% — when using MRI as gold standard.²⁰ Based on this and an increasing amount of data in the literature about ¹⁸F-choline PET/CT for the detection of bone metastases, it seems fair to rely on the findings from ¹⁸F-choline PET/CT with regard to bone metastases. However, with the introduction of PET/CT for M staging of prostate cancer, two problems are important to elaborate on: false-positive results and lead-time bias. M staging of patients with prostate cancer is of great importance for the choice of treatment: patients without distant metastases (M0) will be offered definitive treatment with the expectation of being cured, whereas patients with distant metastases are offered life-prolonging and palliative treatments, and are destined to succumb to their prostate cancer.^{21,22} Thereby, both false-positive and false-negative results have immense consequences. With regard to the ¹⁸F-choline PET/CT used in this study, the false-positive rate has previously been observed in the range of 5% (95% CI 1%–9%).²⁰ In the context of the present study, it seems fair to assume that some of the 12 patients did not have metastatic prostate cancer, but rather false-positive ¹⁸F-choline PET/CT.

In the context of oligometastatic patients in general, clinicians should keep these findings in mind when planning treatment strategy for supposed oligometastatic

prostate cancer patients, since not every lesion that resembles metastasis is in fact a metastatic lesion.²³ To which extend the observed effect of treating oligometastatic patients has been driven by misclassification of M stage is to date unknown. With the introduction of more sensitive imaging modalities, we are able to detect smaller metastatic lesions than prior, which may cause lead-time bias. With an earlier diagnosis of metastatic disease, the time from detection of metastases to death will be prolonged, but the life span of the patient may be unchanged. When we simultaneously introduce new treatments with the new imaging modalities, we may be misled to believe that the observed prolonged time from detection of metastases to death is mediated by the new treatments, when in fact the life span of the patients is unchanged, but only the time of detection of metastases has been changed. Both lead-time bias and false-positive results should be considered when planning treatment strategy for oligometastatic prostate cancer patients, and the management of this difficult patient group may benefit from the use of multidisciplinary conferences. Prostate cancer patients with oligometastatic lesions have been shown to have better cancer-specific and overall survival than patients with widespread metastatic disease.¹³ Besides surgery, new modalities, such as stereotactic body radiotherapy, with highly targeted radiation approaches have been shown to be effective in local control and delaying systemic therapies in men with oligometastatic prostate cancer.^{24,25} Both retrospective and small prospective studies have shown that metastasis-directed ablative therapy using stereotactic body radiotherapy is tolerated and effective in local control and possibly progression-free survival. However, these studies lack consistency in radiation dose and technique; therefore, it is difficult to draw a valid conclusion.

But why did the patients perform so well if they harbored metastases? This may have occurred because they were highly selected oligometastatic patients with limited metastatic burden. Patients had bone scintigraphy that was normal, only one or two bone metastases, and the majority one high risk factor (high PSA, Gleason score, or T stage). By this selection, the 12 patients of the study represent the least severely affected of oligometastatic patients, and both false-positive results and lead-time bias would have been at play. Also, at this early metastatic stage the disease may well be different from how the disease will be 1 or 2 years later, when the bone metastases would have been visible on traditional bone scintigraphy. Since patients in our study were

relatively young and with a metastatic burden limited to a median of only one bone metastasis, they were more fit than most oligometastatic patients in the literature, according to which M1-stage cancer patients have a median survival of only 2.5–3.5 years.^{26,27} Our patients may be more comparable to those in the CHAARTED study, where a subgroup of patients with limited M1 disease was defined.²⁸ When comparing survival, we see resemblances between the patient groups and that patients in an early metastatic state perform better.

Our findings were in line with those of the existing literature. Two trials have been published recently, the larger of which included >2,000 patients, of which >800 were oligometastatic prostate cancer patients. Significantly improved overall survival was found for the oligometastatic patients when radiation of the primary tumor was given together with standard of care compared to standard of care alone.¹³ The other study included >400 patients, of which a third were oligometastatic. Though the setup was like the first study, they did not find a significant change in overall survival when adding radiation of the primary tumor to standard of care. However, a trend toward improved overall survival for oligometastatic patients was observed.¹⁴ More retrospective studies have been published, and the majority have reported survival benefit and reduced local complications following cytoreductive treatments.^{2–4} More prospective studies are on the way, one being G-RAMPP, where patients have been randomized 1:1 between standard drug therapy with or without radical prostatectomy, the end point being prostate cancer-specific survival.²⁹

Limitations of this study have been the size of the cohort, possible selection bias, lead-time bias, and influence of false-positive PET/CT. Finally, the study was initiated more than a decade ago, and in the meantime new more sensitive modalities have arisen, such as prostate-specific membrane-antigen PET/CT and whole-body MRI, which may detect metastatic lesions at an even earlier time point. In conclusion, prospective data from 10 years of follow-up of a small group of patients with oligometastatic hormone-naïve prostate cancer suggest that intended curative treatment of the primary tumor may have a role in highly selected patients.

Disclosure

The authors report no conflicts of interest in this work. JSJ changed position to vice-president, Global R&D at Ferring Pharmaceuticals after finalization of the manuscript.

References

- Mandel P, Steuber T, Graefen M. Radical prostatectomy in oligometastatic prostate cancer. *Curr Opin Urol*. 2017;27(6):572–579. doi:10.1097/MOU.0000000000000445
- Tosoian JJ, Gorin MA, Ross AE, Pienta KJ, Tran PT, Schaeffer EM. Oligometastatic prostate cancer: definitions, clinical outcomes, and treatment considerations. *Nat Rev Urol*. 2017;14(1):15–25. doi:10.1038/nrurol.2016.175
- Tilki D, Pompe RS, Bandini M, et al. Local treatment for metastatic prostate cancer: a systematic review. *Int J Urol*. 2018;25(5):390–403. doi:10.1111/iju.13535
- Slaoui A, Albinini S, Aoun F, et al. A systematic review of contemporary management of oligometastatic prostate cancer: fighting a challenge or tilting at windmills? *World J Urol*. 2019. doi:10.1007/s00345-019-02652-7
- Hellman S, Weichselbaum RR. Oligometastases. *J Clin Oncol*. 1995;13(1):8–10. doi:10.1200/JCO.1995.13.1.8
- Kaplan RN, Riba RD, Zacharoulis S, et al. VEGFR1-positive haematopoietic bone marrow progenitors initiate the pre-metastatic niche. *Nature*. 2005;438(7069):820–827. doi:10.1038/nature04186
- McAllister SS, Gifford AM, Greiner AL, et al. Systemic endocrine instigation of indolent tumor growth requires osteopontin. *Cell*. 2008;133(6):994–1005. doi:10.1016/j.cell.2008.04.045
- de Jong MC, Pulitano C, Ribero D, et al. Rates and patterns of recurrence following curative intent surgery for colorectal liver metastasis: an international multi-institutional analysis of 1669 patients. *Ann Surg*. 2009;250(3):440–448. doi:10.1097/SLA.0b013e3181b4539b
- Fong Y, Fortner J, Sun RL, Brennan MF, Blumgart LH. Clinical score for predicting recurrence after hepatic resection for metastatic colorectal cancer: analysis of 1001 consecutive cases. *Ann Surg*. 1999;230(3):309–18; discussion 18–21.
- Hughes KS, Simon R, Songhorabodi S, et al. Resection of the liver for colorectal carcinoma metastases: a multi-institutional study of patterns of recurrence. *Surgery*. 1986;100(2):278–284.
- Moreno P, de la Quintana Basarrate A, Musholt TJ, et al. Adrenalectomy for solid tumor metastases: results of a multicenter European study. *Surgery*. 2013;154(6):1215–22; discussion 22–3. doi:10.1016/j.surg.2013.06.021
- Strong VE, D'Angelica M, Tang L, et al. Laparoscopic adrenalectomy for isolated adrenal metastasis. *Ann Surg Oncol*. 2007;14(12):3392–3400. doi:10.1245/s10434-007-9520-7
- Parker CC, James ND, Brawley CD, et al. Radiotherapy to the primary tumour for newly diagnosed, metastatic prostate cancer (STAMPEDE): a randomised controlled phase 3 trial. *Lancet (London, England)*. 2018;392(10162):2353–2366. doi:10.1016/S0140-6736(18)32486-3
- Boeve LMS, Hulshof M, Vis AN, et al. Effect on survival of androgen deprivation therapy alone compared to androgen deprivation therapy combined with concurrent radiation therapy to the prostate in patients with primary bone metastatic prostate cancer in a prospective randomised clinical trial: data from the HORRAD trial. *Eur Urol*. 2019;75(3):410–418. doi:10.1016/j.eururo.2018.09.008
- Poulsen MH, Bouchelouche K, Hoiland-Carlson PF, et al. [18F] fluoromethylcholine (FCH) positron emission tomography/computed tomography (PET/CT) for lymph node staging of prostate cancer: a prospective study of 210 patients. *BJU Int*. 2012;110(11):1666–1671. doi:10.1111/j.1464-410X.2012.11150.x
- Kryza D, Tadino V, Filannino MA, Villeret G, Lemoucheux L. Fully automated [18F]fluorocholine synthesis in the TracerLab MX FDG Coincidence synthesizer. *Nucl Med Biol*. 2008;35(2):255–260. doi:10.1016/j.nucmedbio.2007.11.008
- Teras M, Tolvanen T, Johansson JJ, Williams JJ, Knuuti J. Performance of the new generation of whole-body PET/CT scanners: discovery STE and Discovery VCT. *Eur J Nucl Med Mol Imaging*. 2007;34(10):1683–1692. doi:10.1007/s00259-007-0493-3
- DeGrado TR, Reiman RE, Price DT, Wang S, Coleman RE. Pharmacokinetics and radiation dosimetry of 18F-fluorocholine. *J Nucl Med*. 2002;43(1):92–96.
- Shen G, Deng H, Hu S, Jia Z. Comparison of choline-PET/CT, MRI, SPECT, and bone scintigraphy in the diagnosis of bone metastases in patients with prostate cancer: a meta-analysis. *Skeletal Radiol*. 2014;43(11):1503–1513. doi:10.1007/s00256-014-1903-9
- Poulsen MH, Petersen H, Hoiland-Carlson PF, et al. Spine metastases in prostate cancer: comparison of technetium-99m-MDP whole-body bone scintigraphy, [(18) F]choline positron emission tomography-(PET)/computed tomography (CT) and [(18) F]NaF PET/CT. *BJU Int*. 2014;114(6):818–823. doi:10.1111/bju.12599
- Cornford P, Bellmunt J, Bolla M, et al. EAU-ESTRO-SIOG guidelines on prostate cancer. Part II: treatment of relapsing, metastatic, and castration-resistant prostate cancer. *Eur Urol*. 2017;71(4):630–642. doi:10.1016/j.eururo.2016.08.002
- Mottet N, Bellmunt J, Bolla M, et al. EAU-ESTRO-SIOG guidelines on prostate cancer. Part I: screening, diagnosis, and local treatment with curative intent. *Eur Urol*. 2017;71(4):618–629. doi:10.1016/j.eururo.2016.08.003
- Azad GK, Taylor B, Rubello D, Colletti PM, Goh V, Cook GJ. Molecular and functional imaging of bone metastases in breast and prostate cancers: an overview. *Clin Nucl Med*. 2016;41(1):e44–e50. doi:10.1097/RLU.0000000000000993
- Ost P, Reynders D, Decaestecker K, et al. Surveillance or metastasis-directed therapy for oligometastatic prostate cancer recurrence: a prospective, randomized, multicenter phase II trial. *J Clin Oncol*. 2018;36(5):446–453. doi:10.1200/JCO.2017.75.4853
- Niazi T, Elakshar S, Stroiian G. Local ablative stereotactic body radiotherapy for oligometastatic prostate cancer. *Curr Opin Support Palliat Care*. 2018;12(3):351–358. doi:10.1097/SPC.0000000000000371
- Hedlund PO, Damber JE, Hagerman I, et al. Parenteral estrogen versus combined androgen deprivation in the treatment of metastatic prostatic cancer: part 2. Final evaluation of the Scandinavian Prostatic Cancer Group (SPCG) Study No. 5. *Scand J Urol Nephrol*. 2008;42(3):220–229. doi:10.1080/00365590801943274
- James ND, Spears MR, Clarke NW, et al. Survival with newly diagnosed metastatic prostate cancer in the “Docetaxel Era”: data from 917 patients in the control arm of the STAMPEDE trial (MRC PR08, CRUK/06/019). *Eur Urol*. 2015;67(6):1028–1038. doi:10.1016/j.eururo.2014.09.032
- Sweeney CJ, Chen YH, Carducci M, et al. Chemohormonal therapy in metastatic hormone-sensitive prostate cancer. *N Engl J Med*. 2015;373(8):737–746. doi:10.1056/NEJMoa1503747
- Rexer H. Metastatic, hormone-naïve prostate cancer interventional study: multicenter, prospective, randomized study to evaluate the effect of standard drug therapy with or without radical prostatectomy in patients with limited bone metastasized prostate cancer (G-RAMPP - the AUO AP 75/13 study). *Der Urologe Ausg A*. 2015;54(11):1613–1616. doi:10.1007/s00120-015-4020-z

Research and Reports in Urology

Dovepress

Publish your work in this journal

Research and Reports in Urology is an international, peer-reviewed, open access journal publishing original research, reports, editorials, reviews and commentaries on all aspects of adult and pediatric urology in the clinic and laboratory including the following topics: Pathology, pathophysiology of urological disease; Investigation and

treatment of urological disease; Pharmacology of drugs used for the treatment of urological disease. The manuscript management system is completely online and includes a very quick and fair peer-review system, which is all easy to use. Visit <http://www.dovepress.com/testimonials.php> to read real quotes from published authors.

Submit your manuscript here: <https://www.dovepress.com/research-and-reports-in-urology-journal>