

Percutaneous vertebroplasty is safe and effective for cancer-related vertebral compression fractures

Kirkegaard, Andreas Ole; Sørensen, Simon Thorbjørn; Ziegler, Dorthe Schøler; Carreon, Leah; Andersen, Mikkel Østerheden; Rousing, Rikke

Published in:
Danish Medical Journal

Publication date:
2018

Document version:
Final published version

Document license:
CC BY-NC

Citation for pulished version (APA):
Kirkegaard, A. O., Sørensen, S. T., Ziegler, D. S., Carreon, L., Andersen, M. Ø., & Rousing, R. (2018). Percutaneous vertebroplasty is safe and effective for cancer-related vertebral compression fractures. *Danish Medical Journal*, 65(10), [A5509]. <http://ugeskriftet.dk/dmj/percutaneous-vertebroplasty-safe-and-effective-cancer-related-vertebral-compression-fractures>

Go to publication entry in University of Southern Denmark's Research Portal

Terms of use

This work is brought to you by the University of Southern Denmark.
Unless otherwise specified it has been shared according to the terms for self-archiving.
If no other license is stated, these terms apply:

- You may download this work for personal use only.
- You may not further distribute the material or use it for any profit-making activity or commercial gain
- You may freely distribute the URL identifying this open access version

If you believe that this document breaches copyright please contact us providing details and we will investigate your claim.
Please direct all enquiries to puresupport@bib.sdu.dk

Percutaneous vertebroplasty is safe and effective for cancer-related vertebral compression fractures

Andreas Ole Kirkegaard, Simon Thorbjørn Sørensen, Dorthe Schøler Ziegler, Leah Carreon, Mikkel Østerheden Andersen & Rikke Rousing

ABSTRACT

INTRODUCTION: In cancer patients with painful vertebral fractures due to spinal metastasis, traditional pain-relieving therapies include analgesics, bed rest, steroids, radiotherapy, etc. These treatment modalities are often ineffective. Traditional spinal surgery in general anaesthesia is usually not an option in patients with advanced cancer and in a poor general condition. Percutaneous vertebroplasty (PVP) has been reported as a minimally invasive treatment option with apparent rapid pain relief compared with other conventional treatment options. The objective of this study was to assess the safety and efficacy of PVP in patients with malignant spinal lesions.

METHODS: From the National Danish Surgical Spine Database, DaneSpine, 30 consecutive cancer patients with vertebral fractures who underwent PVP from 2013 to 2017 were identified. From DaneSpine, the European Quality of Life – 5 Dimensions Questionnaire (EQ-5D) and the Oswestry Disability Index (ODI) scores were collected pre- and post-operatively. Data on the incidence of complications and poly-methyl methacrylate leaks were obtained by review of medical records and plain post-operative X-rays.

RESULTS: The mean improvement in EQ-5D scores from baseline was 0.30 ($p < 0.01$) after three months, and 0.25 ($p = 0.01$) after one year. The ODI improved from 44.1 to 23.3 ($p < 0.01$). Despite a cement leakage rate of 14.8%, no patients presented with any clinically significant symptoms.

CONCLUSIONS: PVP is a safe procedure providing a statistically significant and clinically relevant improvement in quality of life and function of patients with cancer-related vertebral compression fractures. Our findings may provide useful information to healthcare professionals who are treating cancer.

FUNDING: none.

TRIAL REGISTRATION: not relevant.

In 2012 there were 14.1 million new cancer cases worldwide [1]. The frequency of metastasis to the spine depends on the primary cancer, with the majority of metastasising cancers being breast, lung and prostate cancers [2]. Between 5% and 10% of all cancer patients develop spinal metastases during the course of their disease [3]. This percentage is higher for patients with advanced disease [4].

Treatment options for patients with spinal metastasis are usually palliative, focusing on improving the quality of the remaining life of the patients and their families by reducing or completely eliminating pain. Traditional pain-relieving therapies include analgesics, bed rest, steroids, radiotherapy and radiosurgery [5]. Analgesics and bed rest are often not an effective treatment in cancer patients with painful vertebral fractures due to spinal metastasis. Traditional open instrumented spinal surgery (i.e., the use of medical implants such as rods, screws, etc.) in general anaesthesia is considered to be optimal management. This is usually not an option in patients with advanced cancer and a poor general condition due to short life expectancy and a lengthy hospitalisation and recovery period.

Vertebral augmentation, including vertebroplasty (PVP), has been reported as a minimally invasive treatment option that can be performed on an outpatient basis. The procedure is considered to be well suited for treatment of malignant spine disease because of the proven rapid pain relief compared with the other treatment options [6].

PVP stabilises the fractured vertebrae thereby preventing microscopic movements and macroscopic collapse. Furthermore, it has been suggested that bone cement (poly-methyl methacrylate (PMMA)) induces exothermic reactions that are toxic to the nerve endings [7].

Vertebral augmentation was developed in the late 1980s in France for the treatment of vertebral haemangiomas and osteolytic vertebral tumours [8], but has since gained popularity for treatment of osteoporotic fractures. Under imaging guidance, the needle is traditionally inserted through the pedicles (Figure 1A) [9]. PMMA is injected into the vertebral body under imaging guidance to minimise extravasation. PVP can be performed under local anaesthesia, which prevents prolonged immobilisation [9]. This is of pivotal importance, considering comorbidities and the advanced disease progression of this study population. Additionally, it minimises length of hospitalisation, which may be of great value to the terminally ill patient.

The procedure also provides an opportunity to ob-

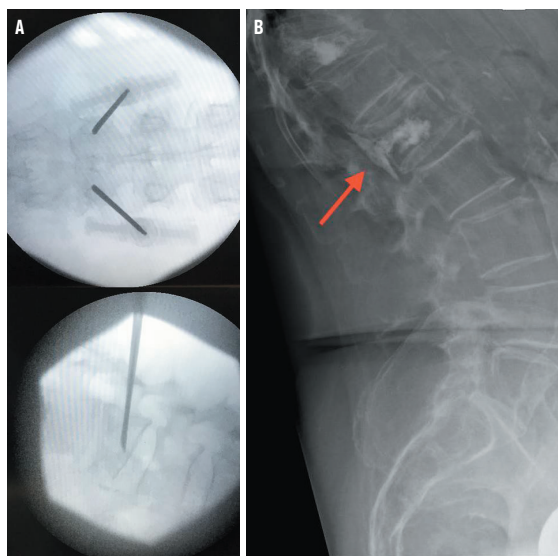
ORIGINAL ARTICLE

Spine Surgery and Research, Spine Centre of Southern Denmark – part of Lillebaelt Hospital, Denmark

Dan Med J
2018;65(10):A5509

 **FIGURE 1**

A. Perioperative X-rays displaying a transpedicular approach.
B. Asymptomatic spinal leakage (arrow) from L1, three months post-operatively in a 78-year-old woman with chronic lymphocytic leukaemia.



tain a bone marrow biopsy prior to cement injection. Studies have shown underlying malignancy in 4.7-4.9% of all patients [10, 11] with vertebral compression fractures initially thought to be due to osteoporosis.

The aim of this study was to determine the safety and efficacy of PVP for vertebral compression fractures caused by malignant spinal disease.

METHODS

This case series included 30 consecutive patients who had been treated with PVP at our institution from 1 January 2013 to 1 March 2017. The patient demographics are presented in **Table 1**. Potential candidates for vertebroplasty at our facility with diagnosed malignant vertebral lesions are primarily referred for evaluation by haematologists, oncologists or general practitioners. The procedure is performed under local anaesthesia, and the patients are usually discharged within the next few hours. Three months post-operatively, the patient is seen for a clinical and radiologic examination of the spine.

The inclusion criteria were: 1) patients treated with PVP for painful vertebral compression fractures at one or more levels; 2) patients with histologically and/or radiologically verified spinal malignancy. In patients with multiple myeloma, a diagnostic bone marrow biopsy prior to the operation was accepted as an eligibility criterion; and 3) patients treated for more than one year prior to the collection of data to allow at least one year of follow-up.

The medical records of all patients treated with PVP at our institution were screened retrospectively, and we obtained information on primary malignancy, histo-

logical examination, magnetic resonance imaging (MRI) evaluations including posterior wall defects and possible complication. Cement leakage was identified using the three-month post-operative X-ray. The remaining data presented in **Table 1** and **Table 2** were extracted from the national spine surgical PRO-database (DaneSpine), which consists of prospectively collected data.

Outcomes were assessed pre- and post-operatively. The primary efficacy outcome was quality of life measured by the European Quality of Life – 5 Dimensions Questionnaire (EQ-5D). Secondary outcomes included the Oswestry Disability Index (ODI) questionnaire, pain, relation between posterior wall defect and complications, and rate of cement leakage. Posterior wall defects were not reported consistently in the MRI descriptions. In the case of a lacking description, two authors re-evaluated the MRI and consulted a radiologist if in doubt.

Data on the EQ-5D and the ODI are expressed as mean \pm standard deviation. Paired t-tests were used to compare these parameters before and after PVP.

Section 1 of the ODI questionnaire was used to assess pain prior to surgery and at the one-year follow-up, since the visual analogue scale (VAS) was not reported consistently. This item categorises pain into one of six statements ranging in severity from “0) I have no pain at the moment” to “5) The pain is the worst imaginable at the moment”. Pain is presented as categorical data in the ODI questionnaire, and a chi-squared test was performed to evaluate the difference between baseline and follow-up.

A threshold p-value of 0.05 was considered significant. All statistical analyses were performed using the Stata 15.0 software.

Trial registration: not relevant.

RESULTS

A total of 22 patients had histologically verified spinal malignancy or a positive bone marrow biopsy from the iliac crest in the case of multiple myeloma. The remaining eight patients all had MRI-confirmed malignant spinal involvement.

PVP was successfully performed on all patients, with a total of 81 vertebrae treated. In all, 17 patients completed questionnaires at the clinical and radiological follow-up at three months. Sixteen patients answered the mailed questionnaire containing the EQ-5D after one year, whereas 17 patients answered the ODI questionnaire after one year. The remaining patients did not answer any of the questionnaires or died before three months post-operatively due to progression of their primary cancer. These patients are included in data analysis on safety only.

Quality of life

The EQ-5D showed an improvement from 0.32 to 0.62 ($p = 0.005$) three months after PVP. This improvement was sustained up to one year post-operatively compared with baseline with an increase from 0.36 to 0.61 ($p = 0.011$) (Table 2).

Mobility

ODI at baseline was 44.1 with a statistically significant improvement to 23.3 ($p = 0.003$) at the one-year follow-up (Table 2).

Pain

Item 1 of the ODI questionnaire regarding pain (Table 3) showed a reduction in median pain from 3 to 2, but no statistical difference between baseline and the one-year follow-up ($p = 0.753$).

Safety

Cement leakage occurred in 12 vertebrae in seven patients, resulting in a leakage rate of 14.8% when calculated per treated vertebra. The leakages were all asymptomatic. No major complications such as spinal cord injury, symptomatic pulmonary embolism or bleeding were observed.

Posterior wall defects were found in 24 of 81 treated vertebrae in 13 patients. One of these defects resulted in cement leakage to the spinal canal, but the patient presented with no neurological symptoms (Figure 1B).

DISCUSSION

In this case series counting 30 patients, statistically significant improvement in both EQ-5D and ODI scores were seen for spinal metastasis treated with PVP at a single institution.

The improvement of the EQ-5D score was 0.30 at three months and 0.25 at 12 months after surgery. Both these score improvements are more than twice the change in EQ-5D scores that is considered the minimum clinically important difference of 0.12 [12]. The improvement in ODI from 44.1 to 23.3 can be interpreted as change from severe disability to moderate disability [13]. This decrease of 20.8 index points is greater than the reported minimum clinically important difference and also greater than the threshold for substantial clinical difference [12]. These improvements in EQ-5D and ODI are similar to previous reports [14].

We evaluated pain using item 1 of the ODI questionnaire, which is less nuanced than VAS, since data on VAS were not collected prospectively. The inability to present a statistically significant reduction in pain might be due to the ordinal nature of the item, with only six possible answers, and to the small sample size.

In addition, this makes it difficult to compare the pain reduction to reductions reported in previously published studies [14].

In this series, the cement leakage rate was 14.8%, which is considerably lower than the rates seen in the majority of previously published studies [14]. Data on injected cement volume was not consistently reported by the operators. If the volume used at our institution is lower than the volume used in previous studies, this might explain the observed difference. Furthermore, the actual rate of cement leakage might be higher if imaged using CT, but this is not standard procedure at our

TABLE 1

Patient demographics.

Patients, total, n	30
Age, mean (range), yrs	69.1 (48-86)
Male, n (%)	20 (66.7)
<i>Primary malignancy, n (%)</i>	
Multiple myeloma	13 (43.3)
Lung	6 (20.0)
Chronic lymphocytic leukaemia	5 (16.7)
Lymphoma	2 (6.7)
Gastric	1 (3.3)
Prostate	1 (3.3)
Colon	1 (3.3)
Ovary	1 (3.3)
<i>Treated levels, n (%)</i>	
Single	6 (20)
Multiple	24 (80)
<i>Treated spine region, n (%)</i>	
Thoracic	37 (45.7)
Lumbar	44 (54.3)
Total	81 (100)
Posterior wall defects, n/N (%)	24/81 (29.6)
Cement leakage, n/N (%)	12/81 (14.8)
Symptomatic complications	0
<i>Survival, n/N (%)</i>	
3 mo.s	23/30 (76.7)
1 yr	18/30 (60)

TABLE 2

Quality of life and mobility outcomes.

	Preoperatively, mean ± SD (n)	Post-operatively, mean ± SD (p-value)	
		3 mo.s	1 yr
EQ-5D ^a	0.32 ± 0.36 (15)	0.62 ± 0.22 (0.005)	-
	0.36 ± 0.38 (14)	-	0.61 ± 0.35 (0.011)
ODI	44.1 ± 19.2 (17)	-	23.3 ± 17.3 (0.003)

EQ-5D = European Quality of Life - 5 Dimensions Questionnaire; ODI = Oswestry Disability Index; SD = standard deviation.

a) Of patients who answered the questionnaire at both baseline and the corresponding follow-up.

 **TABLE 3**

Level of pain at baseline and follow-up.

Level of pain ^a preoperatively	Level of pain 1 yr post-operatively				total, n
	0	1	2	5	
2	2	3	2	0	7
3	1	2	3	1	7
5	0	0	1	0	1
Total	3	5	6	1	15

a) 0 = I have no pain at the moment, 1 = The pain is very mild at the moment, 2 = The pain is moderate at the moment, 3 = The pain is fairly severe at the moment, 4 = The pain is very severe at the moment, 5 = The pain is the worst imaginable at the moment.

institution. Posterior wall defect is, by some clinicians, considered a relative contraindication to PVP because of the perceived higher risk of neurological complications [9]. Similar to the study by Sun et al [15], our results did not indicate any increased risk of complications when treating vertebrae with posterior wall defects.

Our study has some limitations, including missing perioperative biopsies from some patients with multiple myeloma, because the former practice at our institution relied on the bone marrow biopsy and radiological findings alone. This might have led to an overestimation of multiple myeloma patients because we cannot rule out osteoporosis as the cause of these fractures. This has led to a change in the clinical practice at our institution. A biopsy is now standard procedure as part of the PVP despite the establishment of a preoperative diagnosis. We experienced a considerable loss to follow-up due to patient dropout. This is to be expected when conducting studies involving patients in palliative treatment with a limited life expectancy. This might have led to an overestimation of the efficacy since the patients in the best general condition and who enjoyed the largest effect of the treatment participated in the follow-ups. Furthermore, the substantial loss to follow-up meant that we had two different EQ-5D baseline values, when performing the paired t-tests.

The study population included eight patients with spinal malignancy verified by radiology alone. This reduces the diagnostic accuracy, but a sensitivity of 98.5% has been reported when detecting osseous metastasis of the spine using MRI [16].

Finally, our study does not include a control group. This makes us unable to comment on any spontaneous improvement and healing of the fracture. Spontaneous improvements, measured at three months and one year, seem highly unlikely in a study population with advanced cancer. Spontaneous healing of osteoporotic vertebral compression fractures is reported to occur within three months [17], but the natural course of ma-

lignant lesions is a speculative area. The survival rates in this study indicate that these patients might not live long enough to profit from the spontaneous healing of the fracture. An exception to this statement is patients with multiple myeloma who generally survive longer [18].

The only randomised controlled trial on malignant vertebral compression fractures indicates that kyphoplasty (an advanced form of vertebroplasty using a balloon to restore vertebral height) is superior to conservative treatment [19]. The retrospective nature of our study prevents us from utilising blinding, which stops us from quantifying any placebo effect.

In many cases, the patients were referred to our institution late in their oncological treatment. This might lead to a non-malignant biopsy at the time of operation and an underestimation of patients with fractures of a malignant origin.

Cancer patients are at an increased risk of having or developing osteoporosis because of the relatively advanced age at the time of diagnosis and the addition of oncological treatment such as chemotherapy (inducing hypogonadism), hormone ablative therapy, glucocorticoids, surgical castration and irradiation [20]. This leads to the hypothesis that vertebral compression fractures might be caused by a combination of infiltrative neoplastic changes and reduced bone quality.

CONCLUSIONS

Vertebroplasty is a minimally invasive and safe vertebral augmentation therapy for painful vertebral compression fractures in patients with malignant spinal lesions, which makes it ideal for palliative treatment. We showed a statistically significant and clinically relevant increase in quality of life measured by the EQ-5D and mobility measured by the ODI. We observed no difference in the level of pain compared with baseline. To control for confounders and the risks of bias, randomised controlled trials should be performed.

CORRESPONDENCE: Mikkel Østerheden Andersen.

E-mail: mikkell.andersen2@rsyd.dk

ACCEPTED: 14 August 2018

CONFLICTS OF INTEREST: Disclosure forms provided by the authors are available with the full text of this article at Ugeskriftet.dk/dmj

ACKNOWLEDGEMENTS: The authors take this opportunity to extend their gratitude to *Rune Tendal Paulsen* his for assistance with the statistical analysis.

LITERATURE

1. Ferlay J, Soerjomataram I, Dikshit R et al. Cancer incidence and mortality worldwide: sources, methods and major patterns in GLOBOCAN 2012. *Int J Cancer* 2015;136:E359-E386.
2. Patel LR, Camacho DF, Shiozawa Y et al. Mechanisms of cancer cell metastasis to the bone: a multistep process. *Future Oncol* 2011;7:1285-97.
3. Biisky MH, Lis E, Raizer J et al. The diagnosis and treatment of metastatic spinal tumor. *Oncologist* 1999;4:459-69.
4. Macedo F, Ladeira K, Pinho F et al. Bone metastases: an overview. *Oncol Rev* 2017;11:321.
5. Kaloostian PE, Yurter A, Etame AB et al. Palliative strategies for the management of primary and metastatic spinal tumors. *Cancer Control* 2014;21:140-3.

6. Alvarez L, Perez-Higueras A, Quinones D et al. Vertebroplasty in the treatment of vertebral tumors: postprocedural outcome and quality of life. *Eur Spine J* 2003;12:356-60.
7. Trumm CG, Jakobs TF, Zech CJ et al. CT fluoroscopy-guided percutaneous vertebroplasty for the treatment of osteolytic breast cancer metastases: results in 62 sessions with 86 vertebrae treated. *J Vasc Interv Radiol* 2008;19:1596-606.
8. Galibert P, Deramond H, Rosat P et al. Preliminary note on the treatment of vertebral angioma by percutaneous acrylic vertebroplasty. *Neurochirurgie* 1987;33:166-8.
9. Zoarski GH, Stallmeyer MJ, Obuchowski A. Percutaneous vertebroplasty: A to Z. *Tech Vasc Interv Radiol* 2002;5:223-38.
10. Mukherjee S, Thakur B, Bhagawati D et al. Utility of routine biopsy at vertebroplasty in the management of vertebral compression fractures: a tertiary center experience. *J Neurosurg: Spine* 2014;21:687-97.
11. Hansen EJ, Simony A, Carreon L et al. Rate of unsuspected malignancy in patients with vertebral compression fracture undergoing percutaneous vertebroplasty. *Spine* 2016;41:549-52.
12. Glassman SD, Copay AG, Berven SH et al. Defining substantial clinical benefit following lumbar spine arthrodesis. *J Bone Joint Surg Am* 2008;90:1839-47.
13. Fairbank JC, Pynsent PB. The Oswestry Disability Index. *Spine (Phila Pa 1976)* 2000;25:2940-52; discussion 52.
14. Anonymous. Vertebral augmentation involving vertebroplasty or kyphoplasty for cancer-related vertebral compression fractures: a systematic review. *Ontario Health Tech Ass Series* 2016;16:1-202.
15. Sun H, Yang Z, Xu Y et al. Safety of percutaneous vertebroplasty for the treatment of metastatic spinal tumors in patients with posterior wall defects. *Eur Spine J* 2015;24:1768-77.
16. Buhmann Kirchoff S, Becker C, Duerr HR et al. Detection of osseous metastases of the spine: comparison of high resolution multi-detector-CT with MRI. *Eur J Radiol* 2009;69:567-73.
17. Rousing R, Hansen KL, Andersen MO et al. Twelve-months follow-up in forty-nine patients with acute/semiacute osteoporotic vertebral fractures treated conservatively or with percutaneous vertebroplasty: a clinical randomized study. *Spine (Phila Pa 1976)* 2010;35:478-82.
18. Sirohi B, Powles R. Multiple myeloma. *Lancet* 2004;363:875-87.
19. Berenson J, Pflugmacher R, Jarzem P et al. Balloon kyphoplasty versus non-surgical fracture management for treatment of painful vertebral body compression fractures in patients with cancer: a multicentre, randomised controlled trial. *Lancet Oncol* 2011;12:225-35.
20. Rizzoli R, Body JJ, Brandi ML et al. Cancer-associated bone disease. *Osteoporos Int* 2013;24:2929-53.